Diagnostic Trichology and Pattern Hair Loss Medicine

VOLUME 2 | MODULES 5–9

HLI / IIIOHR Advanced Trichology Academy

Volume 2 moves the learner from foundational science into structured, physician-level diagnosis and pattern hair loss medicine. The emphasis throughout is on disciplined observation, clinicopathological reasoning, trichoscopic pattern recognition, investigation planning, and the construction of long-term treatment strategies for male and female patterned hair loss. Every module is designed to develop the systematic thinking required for specialist practice, not simply to enumerate facts.

This volume is written to support both academy manual use and later online delivery on **iiohr.com**. Each module therefore includes learning objectives, lesson architecture, diagnostic frameworks, clinical pearls, red flags, and end-of-module assessment prompts.

Volume 2 at a Glance

The five modules in this volume form a logical diagnostic progression: master the examination, extend it with trichoscopy, investigate intelligently, and then apply integrated reasoning to the two principal pattern hair loss entities. The table below provides an orientation to scope, clinical output, and LMS mapping for each module.

Module	Title	Core Focus	Clinical Output	LMS Mapping
5	Clinical Examination of Hair and Scalp	Structured reproducible examination, grading, photography	Build a reproducible clinical exam	Practical consultation lessons
6	Trichoscopy: Foundations to Advanced Interpretation	Dermoscopic pattern recognition across major disorders	Interpret common and high-risk patterns	Image-atlas and quiz lessons
7	Laboratory Investigations, Endocrine Workup, and Biopsy Logic	Phenotype-led investigation and histologic reasoning	Choose tests and biopsy site logically	Investigation pathways and case reasoning
8	Androgenetic Alopecia in Males	Staging, differential, medical, regenerative, and surgical planning	Diagnose, stage, treat, and plan long term	Treatment ladder and surgery-candidacy lessons
9	Female Pattern Hair Loss and Hormonal Hair Loss in Women	Endocrine integration, reproductive context, and longitudinal management	Integrate endocrine and reproductive logic	Female hair-loss stream and case reviews

Disciplined Observation

Systematic examination protocols that prevent diagnostic omission and ensure reproducible baseline documentation.

Trichoscopic Fluency

Pattern recognition as a clinical language — comparative, site-specific, and integrated with clinical context.

Proportionate Investigation

Hypothesis-driven workup that neither over-medicalises pattern loss nor misses systemic and endocrine drivers.

Long-Term Disease Planning

Treatment strategies framed as partnerships across years, not single interventions at a single time point.

MODULE 5

Clinical Examination of Hair and Scalp

The hair consultation begins before the first instrument is lifted. Pattern, scalp visibility, hairstyle adaptation, eyebrow symmetry, body language, and the distribution of loss all offer clues that no single instrument can fully replace. A strong examiner uses a standard and repeatable order of examination so that subtle patterned miniaturisation, inflammatory disease, breakage, and scarring are not overlooked. This module develops clinical examination as a disciplined, reproducible skill — the necessary foundation on which trichoscopic and laboratory reasoning is built.

1

Learning Objective 1

Conduct a complete and reproducible examination of the hair-bearing scalp and adjacent hair-bearing sites, including eyebrows, lashes, and body hair where relevant.

2

Learning Objective 2

Distinguish between shedding, breakage, and true reduction in follicular density as distinct clinical entities with different implications and differentials.

3

Learning Objective 3

Use validated grading scales and standardised photography protocols to document baseline severity for longitudinal management.

4

Learning Objective 4

Identify clinical red flags that require urgent workup, expedited dermatopathology, or immediate biopsy, and distinguish them from uncomplicated pattern loss.

5.1 Global Visual Inspection and Pattern Recognition

First-Minute Diagnostic Information

The first minute of the consultation — before the patient sits under a lamp or a dermoscope is applied — provides information that cannot be replicated instrumentally. The clinician should observe part-line width, frontal fringe retention, temporal recession, crown see-through, eyebrow density and symmetry, body hair changes where visible, nail examination if systemic disease is suspected, and whether the patient has deliberately styled or applied products to conceal specific zones.

Camouflage behaviour is itself diagnostically meaningful: a patient who consistently brushes hair forward to obscure a thinning crown, or who wears hats regardless of season, is providing pre-verbal information about the location and severity of their concern.

Pattern Recognition as Disciplined Skill

Pattern recognition should be explicitly taught as a disciplined skill rather than an intuitive impression. Male patterned loss most commonly affects the frontotemporal angles, the frontal forelock, the mid-scalp, and the crown in predictable topographic sequences. Female pattern loss more often presents with central part widening, reduced ponytail volume, diffuse crown attenuation, and variable degrees of frontal accentuation with relative preservation of the frontal hairline in many cases.

Diffuse thinning that does not conform to a recognised androgenetic distribution — particularly when preserved or worsening across non-androgenetically programmed zones — should trigger consideration of telogen effluvium, diffuse alopecia areata, chronic systemic illness, medication-related loss, or nutritional deficiency. Scalp symptoms matter: pruritus, pain, burning, perifollicular scale, tenderness, pustulation, and bleeding are not typical primary features of uncomplicated androgenetic alopecia and, when present, indicate inflammatory or cicatricial disease that requires separate diagnostic attention.

5.2 Density, Calibre, and Part-Line Assessment

Density is not merely the number of visible hairs; it is the combined perceptual effect of follicular unit density per unit area, the number of hairs per follicular unit, individual shaft calibre, hair colour contrast against the scalp, curl pattern, shaft length, and the presence or absence of miniaturised hairs intermixed with terminal shafts. A patient with naturally fine-calibre hair may appear objectively thin despite having entirely adequate follicle counts, whereas a patient with coarse, dark hair and genuine early miniaturisation may appear cosmetically acceptable to a casual glance.

Calibre Variability as Diagnostic Clue

Calibre variability — sometimes quantified as anisotrichosis under trichoscopy, but also assessable clinically — is one of the most powerful and underused bedside signs in pattern hair loss diagnosis. A scalp with mixed terminal and vellus-like miniaturised hairs in a patterned distribution strongly supports androgenetic alopecia, even before a dermoscope is applied. By contrast, a scalp populated by uniform-calibre short broken hairs suggests a fragility or breakage disorder and changes the entire clinical approach. In traction-related loss, patterned breakage follows the mechanical vector rather than androgenetic susceptibility zones.

Part-Line Width: A Longitudinal Marker

Part-line width should be assessed in standard central, left parasagittal, and right parasagittal partings. In women, progressive central part widening is the most practical longitudinal marker of worsening patterned loss and can often be demonstrated photographically over time before the patient perceives significant clinical change. Part-line observation should be standardised — the parting should be created in the same location, with the same instrument, and under the same lighting conditions at each follow-up visit, to allow genuinely comparative assessment.

Scalp Reflection and Coverage Index

A practical qualitative assessment used at the bedside is scalp-to-hair coverage ratio: the proportion of the scalp surface that is visible through the hair shafts under direct overhead lighting. This can be graded subjectively (minimal, moderate, substantial) or photographically. Changes in this metric over follow-up are often the clearest signal to a patient that treatment is producing measurable benefit, and documenting it provides defensible objective evidence of disease activity or stabilisation.

5.3 Scalp Examination and Inflammatory Clues

Scalp surface examination should be systematic and should include assessment of erythema distribution and intensity, perifollicular versus diffuse scale, greasy or waxy scale versus dry adherent scale, the presence and integrity of follicular ostia, tufting of multiple hairs from single ostia, pustules or crusts, dyspigmentation including depigmentation and hyperpigmentation, scalp atrophy, and follicular hyperkeratosis or keratotic plugs. Loss of follicular openings (loss of ostia) combined with shiny, atrophic scalp skin should immediately and urgently raise concern for an active cicatricial (scarring) alopecia, which requires urgent biopsy referral.

Distinguishing Scale Subtypes

Scale morphology carries diagnostic weight that is often underappreciated. Fine white loose scale suggests seborrhoeic dermatitis or xerosis; thick silvery adherent scale in a patterned distribution raises psoriasis; tightly adherent perifollicular scale or casts surrounding individual hair shafts are characteristic of lichen planopilaris and should never be attributed to dandruff without further evaluation. Dissecting cellulitis produces boggy scalp, interconnecting sinuses, and a distinctive inflammatory architecture detectable on clinical and trichoscopic examination.

In darker phototypes, erythema may be substantially understated or entirely masked by background pigmentation. Clinicians examining patients with Fitzpatrick skin types IV–VI must rely on texture changes, perifollicular keratosis, tenderness on direct palpation, patient-reported burning, itch, or pain, and the trichoscopic findings at the follicular level to detect active inflammation that may not be visible to the naked eye. Failure to adapt the examination approach to phototype is a significant and avoidable diagnostic error.

Seborrhoeic Dermatitis as Diagnostic Distractor

Seborrhoeic dermatitis is common and ubiquitous in hair loss clinics, and its presence can distract the clinician from concurrent pathology. A patient with visible greasy scale, mild erythema, and diffuse mild pruritus may have seborrhoeic dermatitis as the primary scalp diagnosis, but they may also have co-existing androgenetic alopecia, early lichen planopilaris, or frontal fibrosing alopecia at the hairline margin that would be missed if the examination stops at the seborrhoeic diagnosis. A rigorous examination must always survey the entire scalp and hairline margins irrespective of the apparent primary finding.

Follicular hyperkeratosis, a finding in which individual follicular ostia are surrounded by small keratotic plugs, may indicate follicular lichen planus variants, keratosis follicularis, or discoid lupus in specific clinical contexts. The distribution, associated signs, patient ethnicity, and phototype all contribute to appropriate interpretation.

5.4 Hair Pull Test, Shed Analysis, and Breakage Logic

The hair pull test is among the most frequently performed and most frequently misinterpreted bedside assessments in trichology. It is most informative when performed systematically across multiple scalp regions — frontal, parietal, vertex, occipital, and temporal — and when the result is interpreted within the clinical context of the presentation. Performing the test in a single zone and applying the result globally is a common and avoidable error. A positive pull (extraction of three or more club hairs from a grasped bundle of approximately sixty hairs, using gentle sustained traction without sharp tugging) at the margin of an alopecia areata patch suggests inflammatory activity at that zone. A diffuse positive pull across all scalp regions is consistent with generalised telogen effluvium or diffuse immune-mediated shedding.

1

Step 1: Perform in Multiple Zones

Frontal, parietal, vertex, occipital, and temporal regions tested separately. Compare results across zones.

2

Step 2: Classify Extracted Hairs

Examine root morphology. Club root with depigmented bulb = telogen shed. Absent root or variable-length shaft = breakage.

3

Step 3: Interpret in Clinical Context

A positive pull alone is not a diagnosis. Correlate with time course, history, and the remainder of the examination.

4

Step 4: Integrate with Shed Analysis

Patient-supplied wash test or shed hair samples clarify whether the complaint is active shedding, poor regrowth, or progressive miniaturisation.

Patients almost universally confuse shed hair with broken hair, and this confusion leads to fundamental misunderstanding of the differential diagnosis. Shed telogen hairs characteristically display a depigmented, soft, club-shaped root and are more likely to be full-length or near full-length shaft hairs. Broken hairs lack a distinguishable root bulb, are variable and often short in shaft length, and may show fraying or split ends at the proximal break point. Communicating this distinction to the patient — and demonstrating it with examination or hand-lens inspection of a sample — changes the entire diagnostic conversation. A patient convinced they are shedding excessively may in fact have chronic breakage from heat, chemical, or mechanical stress, requiring an entirely different management approach.

5.5 Standardised Photography and Severity Grading

Photography as a Clinical Instrument

Photography in hair loss medicine is not an administrative task — it is a clinical instrument that directly affects diagnostic accuracy, treatment planning, patient counselling, and medicolegal documentation. Pre-treatment photography should be obtained before any medical, regenerative, or surgical intervention. Without a comparable baseline, longitudinal assessment of treatment response or disease progression is largely subjective and clinically unreliable.

A standardised photography protocol should use fixed or reproducible lighting conditions (ideally a dedicated clinical photography setup rather than variable ambient light), consistent camera-to-patient distance, the same hairstyle preparation at each visit (hair clean, dry, and free of styling products), and a reproducible set of anatomical views for every patient type.

Standard View Protocol (Eight-View Set)

- **Frontal view:** Full-face frontal with hairline and frontal zone clearly visible
- **Frontal oblique (left and right):** Temporal recession and frontotemporal angles
- **Vertex/crown overhead view:** Crown thinning and circular pattern assessment
- **Left and right lateral views:** Mid-scalp transition, temporal profile, sideburn integrity
- **Posterior/donor view:** Occipital density, nape, and donor quality
- **Central part-line close-up:** Width, density, and scalp-to-hair visibility ratio

Additional views — parasagittal partings, hairline margin close-ups, or symptomatic zone close-ups — should be added as clinically indicated.

Severity scales are useful tools when combined with a nuanced clinical narrative, but they should not replace that narrative. The Norwood-Hamilton classification system supports documentation and communication of male pattern hair loss staging; Ludwig, Sinclair, and Olsen descriptors support female pattern documentation. Each scale captures a different aspect of the phenotype. Norwood-Hamilton stages I through VII document the progressive frontotemporal and crown involvement sequence in men; Ludwig grades I through III describe diffuse crown thinning severity in women; Sinclair stages 1 through 5 provide a more inclusive five-level female classification. No scale fully captures donor quality, calibre, hair colour contrast, miniaturisation degree, or the presence of coexisting shedding — all of which materially affect management.

Module 5: Clinical Pearls, Red Flags, and Assessment

🔵 Clinical Pearls

- Always distinguish density loss from reduced calibre; the patient experiences both as 'thinning' but they have entirely different clinical implications, differentials, and management responses.
- Symptoms such as burning, tenderness, pustulation, or perifollicular scale are not explained by uncomplicated pattern hair loss and mandate broader evaluation.
- A careful baseline photograph set is one of the highest-value interventions in long-term hair loss management — clinically, educationally, and medicolegally.
- Camouflage behaviour and hairstyle choices are pre-verbal diagnostic information and should be noted as part of the first-impression assessment.
- Calibre variability is often visible to the naked eye in good lighting; it should be sought before the dermoscope is applied.

🚨 Red Flags Requiring Urgent Workup or Biopsy

- Rapid progression over weeks to a few months without a plausible physiological or pharmacological trigger
- Loss of follicular ostia, scalp pain, perifollicular scale or casts, pustules, or sinus tracts
- Patchy eyebrow loss, body hair reduction, or scalp dyspigmentation in zones not consistent with androgenetic distribution
- Marked diffuse shedding accompanied by systemic symptoms: weight change, fatigue, menstrual disturbance, or fever
- Tufting (polytrichia) or boggy scalp texture suggesting deep follicular destructive process

End-of-Module Assessment Prompts

1. Describe a standard eight-view photography protocol for patterned hair loss and explain why each view is clinically necessary.
2. List bedside findings that favour miniaturisation rather than telogen shedding as the primary mechanism of hair thinning.
3. Explain when a positive hair pull test is clinically meaningful and when it may be misleading as a standalone finding.

MODULE 6

Trichoscopy: Foundations to Advanced Interpretation

Trichoscopy should be treated as a diagnostic language rather than a supplementary gadget. When used with discipline and systematic comparison, it improves diagnostic confidence, supports early detection of pattern hair loss before gross alopecia develops, guides biopsy site selection with accuracy that naked-eye examination cannot match, and provides a reliable platform for longitudinal photographic follow-up. In a physician-level curriculum, learners must understand which trichoscopic findings are high-yield and potentially pathognomonic in context, which are supportive rather than diagnostic, which overlap across disorders, and how specific trichoscopic observations change clinical management.

1

Learning Objective 1

Apply dry and wet (interface fluid) trichoscopy appropriately across different hair and scalp disorders, selecting the technique best suited to the question being asked.

2

Learning Objective 2

Recognise and interpret the trichoscopic patterns associated with male and female pattern hair loss, including signs of early miniaturisation before clinical baldness is established.

3

Learning Objective 3

Identify key trichoscopic signs of alopecia areata, common inflammatory scalp diseases, and cicatricial alopecias, and understand which signs require urgent diagnostic action.

4

Learning Objective 4

Use trichoscopy to select the most informative biopsy site, particularly in suspected scarring alopecia where site selection critically determines diagnostic yield.

6.1 Equipment, Magnification, and Examination Technique

The clinical trichoscope — a handheld dermoscope with polarised and/or non-polarised illumination, or a videodermoscope connected to a monitor — is the core instrument. Handheld dermoscopes used at ×10 to ×20 magnification are widely available, portable, and sufficient for most pattern assessments. Videodermoscopes with variable magnification (×20 to ×200) provide greater resolution for shaft diameter measurement, perifollicular detail, and photographic documentation. Digital trichoscopy with image storage enables comparative longitudinal analysis, which is one of its greatest practical advantages over naked-eye examination.

Lower Magnification (×10–×20)

Global pattern assessment, perifollicular mapping, interfollicular surface features, erythema distribution, overall follicular unit density. Best for first-pass survey.

Intermediate Magnification (×40–×70)

Shaft diameter diversity, terminal-to-vellus ratio, peripilar sign, yellow dots, black dots, broken hairs. Practical for most pattern and alopecia areata assessments.

Higher Magnification (×100–×200)

Shaft surface morphology, cuticular integrity, trichorrhexis, bubble hairs, pseudonits, pilar casts, and subtle vascular patterns in inflammatory disease.

Dry trichoscopy — applied without immersion medium — is the preferred technique for scale morphology and shaft surface disorders. The absence of interface fluid preserves the natural appearance of scale, keratotic casts, and surface texture. Interface fluid (alcohol gel or ultrasound gel) reduces light scatter at the skin surface and improves vascular and follicular detail, making it particularly useful when perifollicular erythema, vascular patterns, or follicular opening morphology are the primary questions. Alternating dry and wet techniques in the same examination session provides complementary information and is a recommended practice in complex or atypical cases.

Site standardisation is essential for comparative validity. Examination should routinely include frontal, mid-scalp, crown, and occipital scalp, and any symptomatic or clinically abnormal zones. The occipital scalp is not merely the donor site assessment area; it is the internal control zone for pattern hair loss evaluation, representing the expected normal baseline in most patients without diffuse disease. Any meaningful comparison between patterned and non-patterned zones must include a reproducible occipital reference.

6.2 Normal Trichoscopic Background

Why Normal Must Be Learned First

Before pathology can be reliably identified, the examiner must internalise the normal trichoscopic range. A common and consequential novice error is overcalling pathology from normal heterogeneity — attributing normal colour variation, hair cycling appearances, and mild follicular unit diversity to disease. This leads to unnecessary investigation, patient anxiety, and premature or inappropriate treatment.

Normal scalp trichoscopy shows follicular units containing one to four hairs (with two to three being most common in the frontoparietal scalp), an interfollicular pigment network of variable complexity depending on skin phototype, occasional empty follicular openings reflecting normal hair cycling rather than disease, and expected site-specific variation in hairs per unit. Occipital units typically contain slightly more hairs per unit than frontal units in most individuals, which is part of why occipital density is preserved in androgenetic alopecia.

Variables That Affect Normal Appearance

- **Hair curl pattern:** Highly textured or afrotextured hair creates unique trichoscopic appearances including pseudonits, shaft coiling, and different follicular unit geometry. These are normal variants, not disease signs.
- **Melanin pigmentation:** Darker phototypes display a more prominent pigment network and different vascular visibility. Hypopigmented areas may reflect post-inflammatory change rather than scar in some contexts.
- **Age:** Progressive greying alters the appearance of individual shafts and reduces colour contrast of any miniaturised hairs against the scalp surface, which can mask early anisotrichosis.
- **Cosmetic treatments:** Colour-treated, bleached, or chemically relaxed hair alters shaft surface appearance and may cause cuticular changes visible under high magnification that are not indicative of structural disease.
- **Scalp site:** Frontal scalp in many individuals naturally contains proportionally fewer hairs per follicular unit than occipital scalp; this should not be interpreted as frontal miniaturisation without supporting features.

6.3 Pattern Hair Loss Under Trichoscopy

The trichoscopic diagnosis of androgenetic alopecia rests on a cluster of supportive findings rather than a single pathognomonic sign, and the overall pattern and zone-specific distribution of these findings is as important as the individual features. The central trichoscopic features supporting pattern hair loss are: increased hair shaft diameter diversity (anisotrichosis), a rising proportion of thin and vellus-like hairs in the androgenetically susceptible zones, reduced average number of hairs per follicular unit in affected areas compared with the occipital control, and in some patients a peripilar sign — a subtle brown perifollicular halo produced by perifollicular lymphocytic infiltration and miniaturisation-associated changes at the infundibulum.

Anisotrichosis

Coexistence of wide-diameter terminal and thin miniaturised shafts within the same follicular units or adjacent units in the affected zone. The degree of anisotrichosis provides a semi-quantitative index of the burden of miniaturisation and correlates with histologic terminal-to-vellus ratio.

Peripilar Sign

A brown perifollicular halo of less than 1 mm diameter surrounding follicular ostia in affected zones. Present in approximately 60–70% of AGA patients. Reflects perifollicular fibrosis and inflammation associated with progressive miniaturisation. Absent in simple telogen effluvium.

Reduced Hairs per Unit

Progressive decline in hairs per follicular unit in the affected zones, contrasting with preserved multi-hair units in the occipital scalp. Quantitative comparison between frontal and occipital sites is one of the most powerful trichoscopic assessments.

Female-Specific Pattern

In women, frontal and midline comparison with occipital scalp is often more informative than any individual sign. Reduced frontal unit count combined with anisotrichosis and widened part-line supports FPHL even when no single sign is dramatic in isolation.

Trichoscopy can detect patterned miniaturisation before gross alopecia is visually dramatic at standard clinical examination distances. This pre-clinical detection is arguably the most important clinical advantage of routine trichoscopy in pattern hair loss, as it allows earlier intervention during the window when follicular rescue is most achievable and the cosmetic impact of treatment is greatest.

6.4 Telogen Effluvium and Diffuse Shedding Patterns

Trichoscopic Features of Acute Telogen Effluvium

Acute telogen effluvium often shows relative preservation of shaft diameter homogeneity compared with androgenetic alopecia — the key distinction being that in pure telogen effluvium the shed and retained hairs are essentially uniform in calibre, reflecting a systemic trigger acting on a follicular population of normal terminal hairs rather than the progressive selective miniaturisation of genetically susceptible follicles. Numerous short regrowing anagen hairs (upright regrowing hairs, sometimes called 'exclamation mark regrowth' when very fine) may appear during the recovery phase following trigger resolution. These short regrowing hairs are a reassuring feature indicating active follicular recovery, but they do not indicate miniaturisation and must not be mistaken for vellus hairs.

In the context of acute telogen effluvium, the peripilar sign is typically absent, follicular units are preserved in number, and the distribution of findings is diffuse and non-patterned — affecting occipital scalp comparably to the frontoparietal scalp, unlike androgenetic alopecia where the occipital zone is the internal normal control.

Mixed Disorder Presentations

In clinical practice, the majority of adult patients presenting with hair loss have mixed or overlapping disorders rather than a single pure diagnosis. Androgenetic alopecia may be compounded by concurrent telogen effluvium triggered by iron deficiency, thyroid dysfunction, postpartum physiology, emotional stress, or surgery. In these patients, the trichoscopic picture will show elements of both conditions: patterned anisotrichosis in susceptible zones overlaid by global density reduction, increased shed hair count, and short regrowing hairs across all scalp sites.

When diffuse shedding coexists with pattern hair loss, the occipital control area and a thorough history become particularly important anchors of interpretation. Trichoscopy should be integrated with the time course, triggers, and laboratory findings rather than interpreted in isolation. A trichoscopic atlas approach — with sequentially acquired and date-stamped comparison images — is particularly valuable in mixed-disorder follow-up to isolate the contribution of each disease component to the observed change over time.

6.5 Alopecia Areata and Immune-Mediated Clues

Alopecia areata produces a distinctive cluster of trichoscopic signs that reflect its underlying immunopathology of follicular anagen arrest and peribulbar lymphocytic infiltration. None of these signs should be read in isolation, but their combination in an appropriate clinical context substantially increases diagnostic confidence and in many cases allows diagnosis without biopsy.

Yellow Dots

Enlarged follicular ostia filled with keratinous and/or sebaceous material, appearing as yellow or yellow-white dots. Present in both active and inactive patches. May be the most reliable single trichoscopic finding in alopecia areata across all skin phototypes.

Black Dots (Cadaverised Hairs)

Residual pigmented hair shaft fragments within the follicular opening, indicating complete shaft breakage at the scalp surface due to anagen arrest. Marker of active disease. Also called 'cadaverised hairs'. More visible in darker hair phototypes.

Exclamation Mark Hairs

Short broken hairs with a narrow proximal shaft widening to normal calibre distally, resembling an exclamation mark. Represent weakened anagen shafts broken by the mechanical stress of hair growth. Highly specific for active alopecia areata when present.

Tapered and Broken Hairs

Varying degrees of proximal shaft narrowing and fraying reflect the spectrum of follicular immune attack. Tapered hairs are actively growing hairs with compromised structural integrity due to peri-infundibular and peribulbar inflammation.

Regrowing Upright Hairs

Short, fine, upright hairs appearing during disease remission or in response to treatment. Indicate follicular recovery. Must be distinguished from vellus-like miniaturised hairs of AGA, which are found in patterned zones rather than diffusely.

Diffuse alopecia areata (alopecia areata incognita) represents one of the most diagnostically challenging hair loss presentations in clinical practice. In this variant, the hallmark patchy distribution of classic alopecia areata is absent, and the presentation is instead of generalised diffuse thinning that may closely mimic telogen effluvium, severe diffuse FPHL, or even thyroid-related shedding. In these cases, trichoscopy — particularly the identification of yellow dots across all scalp zones including the occipital region, and the presence of tapered hairs without calibre heterogeneity in the patterned distribution expected for AGA — may represent the critical difference between a reassuring telogen effluvium diagnosis and a correct immune-mediated diagnosis requiring immunomodulatory treatment. Trichoscopy in this context is genuinely transformative for clinical management.

6.6 Scarring Alopecia Trichoscopy and Biopsy Targeting

Key Scarring Alopecia Trichoscopic Signs

- **Loss of follicular openings:** Absence of ostia in an area of alopecia is the single most important trichoscopic indicator of scarring disease. White structureless areas replacing former follicular zones confirm fibrosis.
- **Perifollicular erythema:** Active inflammatory scarring alopecias (e.g., lichen planopilaris, frontal fibrosing alopecia) typically show perifollicular erythema, which may be subtle in darker phototypes.
- **Perifollicular scale and casts:** Tight keratotic casts or scale surrounding follicular shafts are characteristic of lichen planopilaris and frontal fibrosing alopecia. These are distinct from the loose interfollicular scale of seborrhoeic dermatitis.
- **Tufting (polytrichia):** Multiple hairs (often 6–20+) emerging from a single enlarged follicular ostium, reflecting follicular destruction and follicular unit merger. Characteristic of folliculitis decalvans and dissecting cellulitis.
- **Pustulation and crusting:** Active pustules and haemorrhagic crusts indicate purulent folliculitis and require urgent dermatological management.
- **White structureless areas:** End-stage fibrosis replacing former follicular terrain. No further intervention will regenerate follicles in these zones.

Biopsy Site Selection in Suspected Scarring Alopecia

Trichoscopy-guided biopsy site selection is arguably the most clinically impactful application of trichoscopy in specialist practice. The most informative biopsy site in suspected or confirmed cicatricial alopecia is the active advancing margin — a zone where perifollicular scale, erythema, or inflammatory signs are present trichoscopically but where follicles and follicular openings are still partially visible. Biopsying the burned-out, white, featureless centre of an established scar provides architectural information about the extent of destruction but almost no information about the pathological process responsible for it, because the diagnostic inflammatory infiltrate has regressed.

The advancing margin with perifollicular change and at least some residual follicular structures represents the 'active front' of the disease. This is where the follicular destruction is ongoing, the diagnostic inflammatory infiltrate is maximal, and the likelihood of recovering a histologically diagnostic specimen is highest. In lichen planopilaris, this typically means targeting a zone 5–15 mm behind the hairline margin where erythema and peripilar scaling are still active. In dissecting cellulitis, it means targeting fluctuant or erythematous nodules rather than the established sinus tract network.

Trichoscopy is not a substitute for histology in suspected scarring disease — it can suggest the category of process but cannot provide the tissue diagnosis that determines systemic treatment decisions. Its role is to maximise diagnostic yield by directing where and when to biopsy.

6.7 Reporting Standards, Longitudinal Follow-up, and Module 6 Assessment

A trichoscopy report that documents clinical utility should state: the sites examined, the magnification and technique used (dry versus wet), the comparison zones evaluated, and the specific findings that changed or supported management. Avoid generating lengthy descriptive catalogues of every visible feature without linking the findings to a clinical conclusion. The value of a trichoscopy report lies in its interpretive content, not its descriptive volume.

🔵 Clinical Pearls

- Trichoscopy is most powerful when used comparatively: affected zone versus the occipital control zone within the same patient at the same visit.
- Early pattern hair loss can be clinically subtle to the naked eye but trichoscopically obvious — routine trichoscopy at first consultation prevents missed early diagnoses.
- The best biopsy site in scarring alopecia is almost always identified trichoscopically rather than by naked-eye inspection of the largest bald area.
- Longitudinal trichoscopy with time-stamped comparable images is one of the strongest objective monitoring tools in long-term hair loss management.

🚨 Red Flags

- Loss of ostia combined with symptoms of burning or tenderness — urgent biopsy planning required
- Tufting, pustules, perifollicular casts, or structureless white areas indicating active or end-stage scarring
- Diffuse yellow dots and tapered hairs in a pattern mimicking telogen effluvium — suspect diffuse alopecia areata incognita

End-of-Module Assessment Prompts

1. List the trichoscopic findings that support a diagnosis of androgenetic alopecia and explain why the occipital scalp is used as a comparator.
2. Explain how dry and wet trichoscopy differ in their preferred applications and what each technique optimally reveals.
3. Describe how trichoscopy helps select a biopsy site in suspected scarring alopecia and explain why the centre of an established scar is an unreliable biopsy target.

MODULE 7

Laboratory Investigations, Endocrine Workup, and Biopsy Logic

Physicians should not order indiscriminate hair-loss blood panels — but neither should they under-investigate patients with diffuse shedding, menstrual disturbance, hyperandrogenic clinical clues, nutritional risk, autoimmune history, or inflammatory disease. The best workup is phenotype-led and hypothesis-driven, beginning with a careful history and examination and constructing a targeted investigation strategy around the specific differential diagnosis rather than reflexively ordering a fixed 'hair-loss screen' for every patient regardless of presentation.

1

Learning Objective 1

Select laboratory investigations based on the specific phenotype, clinical history, and differential diagnosis rather than applying a universal investigation panel to all hair loss patients.

2

Learning Objective 2

Interpret common blood markers — including iron studies, thyroid function, androgen levels, and inflammatory markers — in the specific context of shedding and patterned hair loss rather than in isolation.

3

Learning Objective 3

Know when scalp biopsy is indicated, how to select the optimal site using clinical and trichoscopic information, and how to communicate effectively with the pathologist to maximise diagnostic yield.

4

Learning Objective 4

Integrate laboratory and histologic data with clinical examination and trichoscopic findings to generate a clinicopathological diagnosis rather than relying on any single data source in isolation.

7.1 Principles of a Phenotype-Led Workup

The concept of proportionate investigation — calibrating test ordering to the probability and risk implications of the conditions under consideration — is central to physician-level trichology practice. Classic male patterned hair loss presenting in a man with a strong family history, typical Norwood staging, no systemic symptoms, no medications known to cause hair loss, and a straightforward history can typically be diagnosed clinically and managed without laboratory investigation. Ordering a full blood count, thyroid function, testosterone, and ferritin in this patient serves no investigative purpose and medicalises a straightforward diagnosis unnecessarily.

By contrast, diffuse shedding of sudden onset, menstrual irregularity, hirsutism, severe acne in a female patient, marked fatigue, major dietary restriction, recent significant weight change, personal or family history of autoimmune disease, or inflammatory scalp findings should prompt targeted investigation. The physician's clinical reasoning must identify which conditions are plausible explanations for the presentation in this individual patient and investigate those specifically.

High Investigation Priority

Diffuse shedding of acute onset; menstrual disturbance; hyperandrogenic features (hirsutism, acne, virilisation); significant dietary restriction; known or suspected systemic disease; autoimmune history; inflammatory scalp signs; rapid progression without clear trigger.

Moderate Investigation Priority

Female patterned loss at any age (iron, thyroid, SHBG baseline); male patterned loss with atypical features; postpartum shedding beyond 12 months; fatigue with hair loss; post-bariatric or post-surgical presentation; shedding with dietary concerns.

Low Investigation Priority

Classic male AGA in a healthy man with positive family history, typical topographic pattern, stable progression, and no systemic symptoms. Diagnosis is clinical; investigation should follow phenotype, not habit or protocol.

7.2 Core Laboratory Markers in Diffuse Shedding and Female Hair Loss

For patients with diffuse shedding, female pattern hair loss, or any presentation where systemic causes are possible, a core laboratory panel should be considered in the context of the clinical picture. The following markers are commonly relevant, though not every test is appropriate for every patient.

Investigation	Relevance in Hair Loss Context	Interpretation Notes
Full blood count	Anaemia, macrocytosis, neutrophilia, eosinophilia	Microcytic anaemia supports iron deficiency; macrocytosis may indicate B12/folate deficiency or alcohol use
Serum ferritin + iron saturation	Iron availability for follicular cycling; most commonly investigated nutritional marker in hair loss	Ferritin is an acute-phase reactant; elevated ferritin in the setting of inflammation does not exclude functional iron deficiency. Interpret with transferrin saturation and clinical context. Optimal ferritin threshold for hair loss management remains debated (commonly cited: >40–70 ng/mL)
Thyroid function (TSH ± FT4)	Hypothyroidism and hyperthyroidism both cause shedding, texture change, eyebrow loss, and nail changes	Mild subclinical abnormalities require correlation with symptoms and referral to general medicine for thyroid-specific management rather than treatment by the trichologist alone
25-OH Vitamin D	Potential role in follicular cycling and immune regulation; commonly deficient in populations with limited sun exposure or dietary restriction	Deficiency is common; treatment of confirmed deficiency is appropriate as general health optimisation. Evidence for direct hair benefit remains supportive rather than conclusive.
Vitamin B12 and folate	Macrocytic anaemia; relevant in vegan/vegetarian patients, bariatric surgery, chronic metformin or proton-pump inhibitor use	Must be interpreted alongside red cell indices and clinical context
ESR / CRP	Systemic inflammation screening; relevant in suspected autoimmune or inflammatory disease	Non-specific; value lies in supporting or refuting suspected systemic disease, not as a standalone hair-loss investigation
Zinc	Nutritional deficiency; more relevant in restrictive diets, malabsorption, bariatric surgery	Borderline serum zinc does not reliably reflect tissue availability; clinical context determines weight given to the result

Ferritin interpretation deserves particular attention because it is simultaneously the most commonly ordered and most commonly misinterpreted marker in hair loss practice. Inflammation of any cause — active infection, inflammatory bowel disease, rheumatoid arthritis, even recent vigorous exercise — drives ferritin upward as an acute-phase response. A 'normal' or even elevated ferritin in the setting of active inflammation may therefore mask true functional iron insufficiency. The treating physician must always interpret ferritin within the context of the full iron panel (including transferrin saturation, serum iron, and total iron-binding capacity), the menstrual and dietary history, and any concurrent inflammatory condition before concluding that iron status is adequate.

7.3 Hyperandrogenism and Endocrine Assessment in Women

When to Investigate Androgens

Women with female pattern hair loss do not all require an androgen panel. The majority of women with FPHL have androgens within the conventional laboratory reference range, and ordering testosterone levels in a woman with straightforward central part widening and a family history of female pattern loss serves limited investigative purpose. However, targeted androgen assessment is most useful — and clinically appropriate — in the presence of objective or subjective signs of androgen excess or endocrine disturbance: irregular menstrual cycles, oligomenorrhoea or amenorrhoea, infertility, severe or persistent inflammatory acne in an adult woman, hirsutism with terminal hair growth in androgen-sensitive sites, obesity in combination with clinical features suggesting insulin resistance, acanthosis nigricans, or rapid and severe onset of hair loss with no other plausible explanation.

Endocrine Investigation Panel

When androgen assessment is clinically indicated, the following markers may be relevant, with the specific panel tailored to the clinical hypothesis:

- **Total testosterone:** Gross androgen excess screening. Total testosterone significantly above the reference range warrants investigation for androgen-secreting tumour, particularly if onset is rapid.
- **Free testosterone or calculated free androgen index (FAI):** More sensitive to bioavailable androgen than total testosterone alone, particularly in women with low SHBG driving higher free fraction despite normal total levels.
- **Sex hormone binding globulin (SHBG):** Low SHBG increases free androgen bioavailability. Reduced by insulin resistance, obesity, hypothyroidism, and certain progestogens.
- **DHEAS:** Adrenal androgen marker. Markedly elevated DHEAS raises concern for adrenal tumour or late-onset congenital adrenal hyperplasia.
- **17-OH progesterone:** Screen for non-classical/late-onset congenital adrenal hyperplasia (21-hydroxylase deficiency) in women with severe hyperandrogenism, particularly in ethnically predisposed populations.
- **Prolactin:** Hyperprolactinaemia can contribute to androgen-mediated hair loss and menstrual disturbance; assess when menstrual irregularity or galactorrhoea is present.
- **LH and FSH:** Elevated LH:FSH ratio supports PCOS; elevated FSH in the menopausal range helps contextualise perimenopausal hormonal shifts in older women.
- **Fasting glucose and insulin, HbA1c:** Metabolic screening for insulin resistance, particularly relevant in PCOS presentations with overweight, acanthosis nigricans, or central adiposity.

7.4 Additional Investigations and System Review

Beyond the core iron, thyroid, and androgen panel, real-world hair loss presentations frequently require broader contextual investigation. The following conditions represent genuine components of the clinical differential in appropriate patients, not merely theoretical considerations.

Autoimmune Screening

Antinuclear antibody (ANA), anti-dsDNA, anti-Ro/La, and complement levels may be appropriate in women with diffuse or patchy hair loss, photosensitivity, oral ulceration, joint symptoms, or other features raising concern for lupus erythematosus or other connective tissue disease. Alopecia may be the presenting feature of systemic lupus. Discoid lupus erythematosus can present as a scarring alopecia with a distinctive trichoscopic and histologic profile. Anti-thyroid antibodies (anti-TPO, anti-thyroglobulin) may be relevant in patients with borderline thyroid function or clinical features of autoimmune thyroiditis even without overt hypothyroidism.

Secondary Syphilis and Infectious Causes

Secondary syphilis produces a classic moth-eaten alopecia with a distinctive patchy non-scarring distribution that can mimic alopecia areata or other inflammatory causes. RPR or VDRL with confirmatory treponemal antibody testing should be included in the differential of unexplained patchy alopecia, particularly in sexually active individuals or those with other mucocutaneous features of secondary syphilis. HIV-associated hair loss, fungal kerion, and tinea capitis should be considered in appropriate epidemiological contexts.

Medication Review and Pharmacological Causes

A comprehensive medication review is a mandatory component of every hair loss workup. Telogen effluvium can be caused by anticoagulants (particularly heparins), antiretrovirals, oral retinoids, interferons, lithium, levodopa, beta-blockers, ACE inhibitors, heavy metals, and numerous other medications. Anagen effluvium is caused by chemotherapy and radiation. Androgenic progestogens in oral contraceptives or hormonal intrauterine devices can exacerbate or unmask androgenetic alopecia in susceptible women. The temporal relationship between drug initiation or dose change and the onset of shedding is the critical diagnostic clue.

Nutritional Assessment Beyond Iron

In patients with a history of bariatric surgery, restrictive eating disorders, prolonged vegan/raw-food diets, inflammatory bowel disease, or significant malabsorption, a broader nutritional screen including B12, folate, zinc, copper, selenium, and protein status (albumin) may be warranted. Post-bariatric telogen effluvium is common, highly characteristic in its time course (onset 3–6 months post-operatively), and often undertreated because the hair loss is attributed to the expected post-surgical course rather than investigated for modifiable nutritional deficiency.

7.5 Biopsy Indications

Scalp biopsy becomes important — and in some clinical situations, mandatory for responsible management — in a defined set of circumstances. Pattern hair loss alone does not usually require biopsy when the clinicotrichoscopic evidence is strong, the history is consistent, and the patient responds as expected to initial management. However, there are multiple scenarios in which biopsy is the appropriate next step.

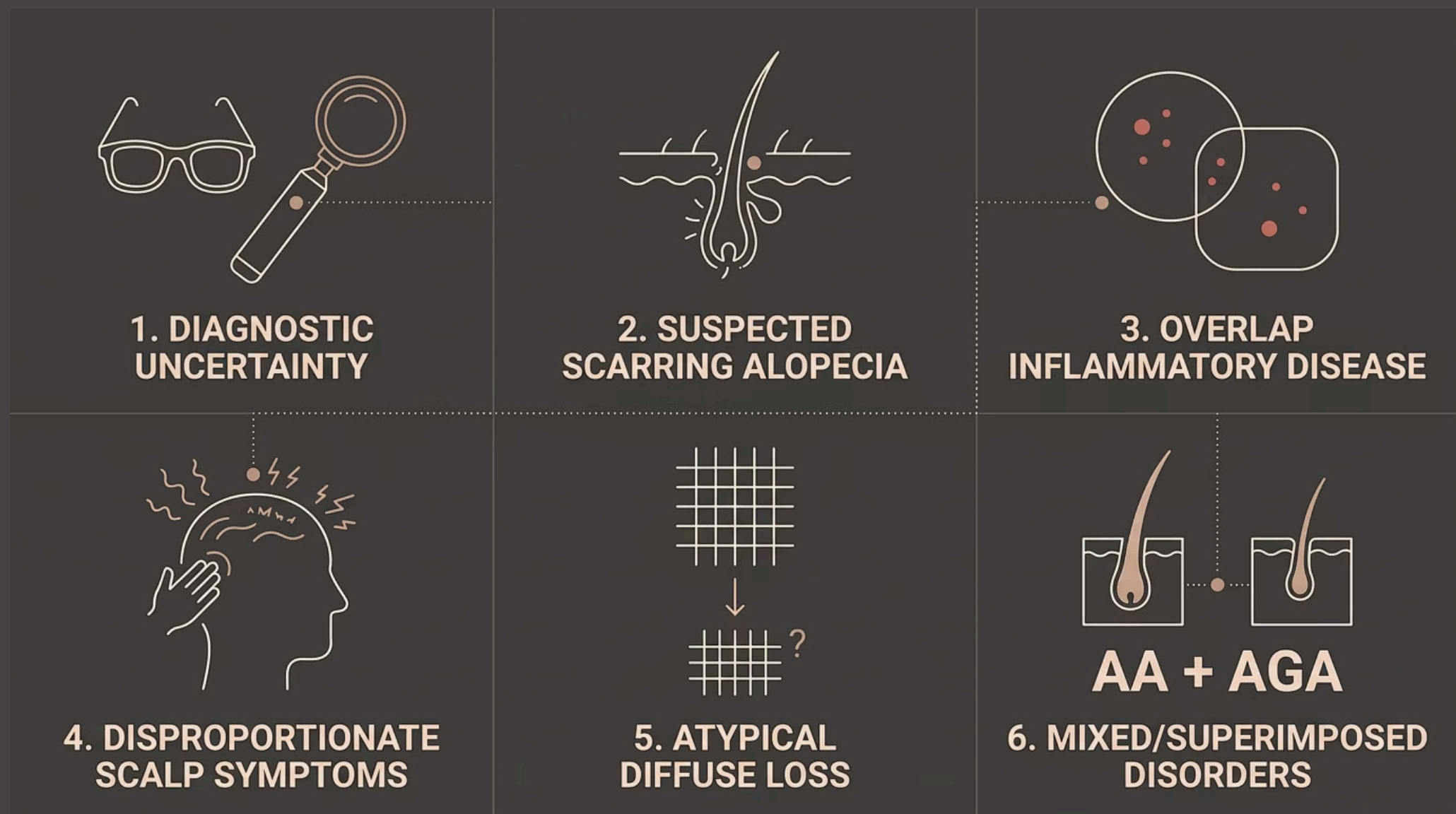

Biopsy can also be valuable in women with mixed presentations, particularly when FPHL and diffuse alopecia areata or early scarring disease cannot be reliably distinguished by examination and trichoscopy alone. A normal or near-normal scalp biopsy in a patient with significant hair loss complaint who has not responded to initial therapy is also clinically informative — it may redirect the workup toward systemic, psychiatric, or non-follicular explanations, or suggest a functional diagnosis requiring a fundamentally different management approach.

7.6–7.7 Biopsy Site Selection, Sectioning, and Clinicopathological Correlation

Site Selection Principles

A poorly selected biopsy site wastes the diagnostic opportunity entirely and produces a histological report that describes the architectural wreckage of end-stage fibrosis rather than the active pathological process. The ideal site is active but not fully destroyed: an advancing symptomatic margin with perifollicular inflammatory change, trichoscopic evidence of active disease, and at least some residual follicular openings visible. In practical terms, this usually means a 4 mm punch biopsy at the active advancing margin of a scarring alopecia patch, a nodule or erythematous zone in dissecting cellulitis, or an area of perifollicular scale and erythema in suspected lichen planopilaris or frontal fibrosing alopecia.

In non-scarring alopecias requiring biopsy — such as diagnostically uncertain diffuse loss or suspected alopecia areata — the site should be chosen from the most clinically affected zone where diagnostic infiltrate is most likely to be present, guided by trichoscopic findings rather than by visual estimate of severity alone.

Clinical information accompanying the specimen materially and measurably improves histologic interpretation. The biopsy request form should include: time course of loss and symptom duration, scalp symptoms, clinical diagnosis under consideration and the specific diagnostic uncertainty being investigated, trichoscopic findings, any treatments already applied (particularly corticosteroids, which suppress infiltrate), and whether horizontal or vertical sections are preferred at the local laboratory.

Sectioning Planes: Horizontal vs. Vertical

Horizontal (transverse) sections cut perpendicular to the long axis of the hair follicle through the mid-follicular level, providing a cross-sectional survey of all follicular structures in the biopsy cylinder simultaneously. This technique is particularly valuable for:

- Quantitative assessment of total follicle number per unit area
- Determination of terminal-to-vellus follicle ratio (the definitive histologic marker of AGA miniaturisation)
- Assessment of perifollicular fibrosis and inflammation distribution
- Distinguishing androgenetic alopecia from chronic telogen effluvium histologically

Vertical (longitudinal) sections follow the long axis of the follicle and provide superior assessment of:

- Interface changes at the follicular epithelium (critical for lichen planopilaris, discoid lupus)
- Perifollicular inflammation at specific anatomical levels (infundibulum, isthmus, bulb)
- Deeper follicular anatomy and bulb morphology
- Fibrous tract remnants indicating prior follicular destruction

Many expert dermatopathology services use step sections combining both planes, or serial sections, to extract maximal diagnostic information from a single 4 mm punch. Understanding the limitations of each sectioning approach helps the clinician formulate a better biopsy request and have a more productive dialogue with the pathologist about the specific diagnostic question.

> **Key principle:** Histology does not exist in a vacuum. The physician's role is not to ask 'What did the biopsy say?' but to determine 'How do the biopsy findings, scalp symptoms, clinical examination, and trichoscopy fit together?' Clinicopathological integration is the mark of expert diagnostic reasoning.

Module 7: Clinical Pearls, Red Flags, and Assessment

🔵 Clinical Pearls

- Investigation strategy should follow phenotype and probability, not habit or a universal hair-loss protocol applied regardless of presentation.
- Most biopsy failures are site-selection failures rather than pathology processing failures — the diagnostic yield is almost entirely determined by whether the active margin is sampled.
- Clinical notes sent with the biopsy materially improve histologic interpretation; the pathologist can only report what the tissue shows without knowing the clinical context that gives it meaning.
- Ferritin must always be interpreted alongside the full iron panel, menstrual history, and any current inflammatory conditions before conclusions about iron adequacy are drawn.
- A temporal relationship between medication initiation and shedding onset is the most diagnostically useful feature of drug-induced hair loss and should be sought in every history.

🚨 Red Flags

- Diffuse loss with constitutional symptoms including fatigue, weight loss, fever, or joint pain — systemic disease workup required beyond hair-specific investigations
- Menstrual disturbance, infertility, hirsutism, or virilisation in women — androgen excess evaluation required, including exclusion of androgen-secreting tumour if testosterone is markedly elevated
- Painful scalp, perifollicular change, or loss of ostia — biopsy should not be deferred
- Failure of a seemingly straightforward diagnosis to respond to a well-conducted initial treatment plan — reconsider the diagnosis and consider biopsy
- Rapid-onset severe diffuse loss without a pharmacological or physiological trigger identifiable in the history

End-of-Module Assessment Prompts

1. Outline a targeted first-line laboratory workup for diffuse shedding in a 32-year-old woman, justifying each test based on the clinical phenotype rather than habit.
2. List the clinical, trichoscopic, and historical features that should prompt scalp biopsy.
3. Explain why biopsying the centre of a fully established scarred patch often yields a non-diagnostic histological report and describe what the ideal biopsy site looks like.

MODULE 8

Androgenetic Alopecia in Males

Male androgenetic alopecia is the most common cause of hair loss in men worldwide, affecting approximately 50% of men by age 50 and up to 80% of men by age 70 in populations of predominantly Northern European ancestry. Despite its prevalence, managing it well at a specialist level is not trivial. The skilled physician does more than diagnose a Norwood stage: they estimate future pattern evolution based on age, family history, and current trajectory; identify aggravating shedding disorders that may be compounding the presentation; assess donor stability and surgical candidacy; discuss the evidence base and realistic expectations for medical and surgical interventions; and frame treatment as a long-term disease-management partnership rather than a one-time cosmetic consultation.

1

Learning Objective 1

Diagnose and stage male pattern hair loss using integrated clinical examination, Norwood-Hamilton staging, and trichoscopic findings, and differentiate uncomplicated male AGA from common mimics and overlap disorders.

2

Learning Objective 2

Construct an evidence-based, stepwise medical and regenerative treatment plan that accounts for degree of loss, age, progression rate, patient preference, and contraindications to specific agents.

3

Learning Objective 3

Assess surgical candidacy in male AGA using a multifactorial framework that incorporates donor assessment, progression risk, realistic expectations, and the interaction between surgery and ongoing medical management.

4

Learning Objective 4

Conduct a structured treatment failure analysis to identify whether apparent non-response reflects incorrect diagnosis, poor adherence, unrealistic expectations, or inadequate treatment design.

8.1 Epidemiology, Genetics, and Age-Linked Activation

Genetic Basis and Inheritance Pattern

Male AGA is a genetically influenced, androgen-dependent miniaturisation process. The genetic susceptibility is polygenic — determined by the additive effects of multiple loci rather than a single gene — and the most significant genetic contribution identified to date involves the androgen receptor gene on the X chromosome. This explains why maternal family history has historically been considered the strongest genetic predictor, though paternal inheritance and autosomal loci contribute meaningfully to the observed familial pattern. Contemporary genome-wide association studies have identified more than 600 genomic loci with association signals for AGA, underscoring the polygenic complexity of the trait.

Susceptible follicles do not all miniaturise simultaneously or at a fixed age; this explains the wide inter-individual variability in onset timing and progression rate even among men with identically strong family histories. A man may carry a fully expressed genetic load for aggressive AGA yet maintain near-complete density until his late thirties or beyond, if his androgen exposure, follicular sensitivity threshold, and individual biological programming align in a manner that delays initiation. The clinician should explain to patients that genes create susceptibility, while the timing and tempo of expression vary considerably between individuals — moving the conversation away from simplistic causal narratives about shampoo choice, hat-wearing, scalp circulation, or short-term physical stressors.

DHT, Miniaturisation, and Follicular Biology

The androgen pathway central to male AGA involves the intrafollicular conversion of testosterone to dihydrotestosterone (DHT) by 5-alpha-reductase type 2 (and type 1 in sebaceous units). DHT binds to the androgen receptor within susceptible dermal papilla cells, activating transcriptional programmes that shorten the anagen phase with successive cycles, reduce follicular volume, and progressively convert the follicle from a terminal hair-producing unit to a vellus-like miniaturised structure. The miniaturisation process is gradual and reversible in its early stages — the fibrous tract below the miniaturised follicle is preserved and the follicular stem cell niche retains regenerative potential — but becomes increasingly irreversible with prolonged disease duration and progressive fibrous replacement of the follicular architecture.

5-alpha-reductase type 2 is predominantly expressed in the outer root sheath and dermal papilla of scalp follicles. Finasteride inhibits type 2 selectively; dutasteride inhibits both type 1 and type 2 isoforms, producing greater systemic DHT suppression. The clinical relevance of this biochemical difference manifests in the greater DHT-lowering potency of dutasteride and its potential for greater efficacy in some men with more treatment-resistant disease, offset by its greater systemic DHT suppression and correspondingly greater potential for sexual and systemic side effects.

8.2 Clinical Phenotype and Staging

The Norwood-Hamilton classification divides male pattern hair loss into seven primary stages with substages, providing a standardised communication framework and a practical basis for surgical planning, clinical research, and patient education. However, the treating physician must supplement staging with a qualitative description of phenotype features that the scale does not capture.

Stage I–II

Minimal frontotemporal recession. Frontal forelock intact. Minimal to no crown involvement. Family history and trichoscopic monitoring are the most important clinical interventions at this stage.

Stage IV–V

Significant frontal-crown connection forming or established. Mid-scalp thinning increasingly visible. Donor assessment and progression planning become central clinical priorities alongside maximising medical therapy.

Stage III / IIIa

Moderate bitemporal recession (III) or frontal thinning extending posteriorly (IIIa). Stage IIIv adds vertex involvement. Typically the stage at which most men first seek medical advice. Intervention is most effective here.

Stage VI–VII

Extensive loss with bridge loss (VI) or only horseshoe pattern remaining (VII). Surgical planning highly dependent on donor quality and long-term crown management strategy. Medical maintenance for remaining native hairs is paramount.

Beyond staging, the clinician must document: donor density and evidence of donor miniaturisation (critical for surgical candidacy assessment); calibre of remaining terminal hairs (coarse versus fine calibre determines cosmetic coverage per graft in surgical planning); hair colour contrast against scalp background (high contrast hair in a fair scalp creates more cosmetic impact per graft but also makes thinning more visible); scalp laxity in the donor zone; degree of miniaturisation in patterned zones as assessed trichoscopically; and whether diffuse patterned thinning affects zones beyond the classic Norwood topography. Young patients with aggressive bitemporal change and diffuse frontal miniaturisation require long-view planning rather than reactive surgical hairline restoration alone, as premature intervention without medical disease control can produce cosmetically compromised results as the disease continues to progress behind and beyond the transplanted zones.

8.3 Trichoscopy and Differential Diagnosis in Male AGA

In male AGA, trichoscopy typically demonstrates anisotrichosis most prominently in the frontotemporal and mid-scalp zones, with relative preservation of follicular unit density and calibre uniformity in the occipital reference zone. A rising proportion of vellus-like hairs intermixed with remaining terminal shafts in affected areas, reduced hairs per follicular unit, and the peripilar sign in approximately 60% of patients complete the classic picture. However, several clinically important differential diagnoses and coexisting conditions may modify the trichoscopic and clinical picture and require recognition.

Telogen Effluvium Overlay

Active shedding from a concurrent trigger (iron deficiency, illness, stress, medication) may amplify the perceived rate of hair loss far beyond what AGA progression alone would produce. Trichoscopy shows diffuse short regrowing hairs across all zones including the occipital control. Management of the concurrent trigger often produces meaningful clinical improvement that the patient misattributes to the AGA treatment, creating a useful therapeutic alliance.

Alopecia Areata Incognita

Diffuse alopecia areata can mimic rapidly progressive male AGA. Yellow dots across all scalp zones — including the occipital reference — combined with an absence of peripilar sign and the presence of tapered or broken hairs should raise suspicion. Importantly, this diagnosis completely changes the treatment plan.

Seborrhoeic Dermatitis

Very common co-morbidity in men with AGA. Visible scale, erythema, and pruritus in a sebaceous distribution do not change the AGA diagnosis but require concurrent management. Active seborrhoeic dermatitis may exacerbate perceived shedding via telogen shift and reduce treatment adherence if scalp comfort is not addressed.

Early Cicatricial Disease

Frontal fibrosing alopecia can present in men as subtle frontotemporal recession mimicking AGA. The bandlike recession pattern, perifollicular erythema, and peripilar scale visible trichoscopically at the hairline margin, combined with loss of follicular ostia at the advancing edge, should prevent misdiagnosis as simple early male AGA. Biopsy and specialist management are appropriate.

8.4 Medical Treatment Ladder in Male AGA

Treatment of male AGA should be framed as disease management rather than cosmetic enhancement. The goal of first-line medical therapy is, in most patients, stabilisation of ongoing miniaturisation and prevention of further loss, with regrowth representing an additional benefit that varies substantially between individuals. Establishing realistic expectations at the outset — that treatment works primarily to slow or stop progression, with variable and often modest regrowth — is essential for long-term treatment adherence and patient satisfaction.

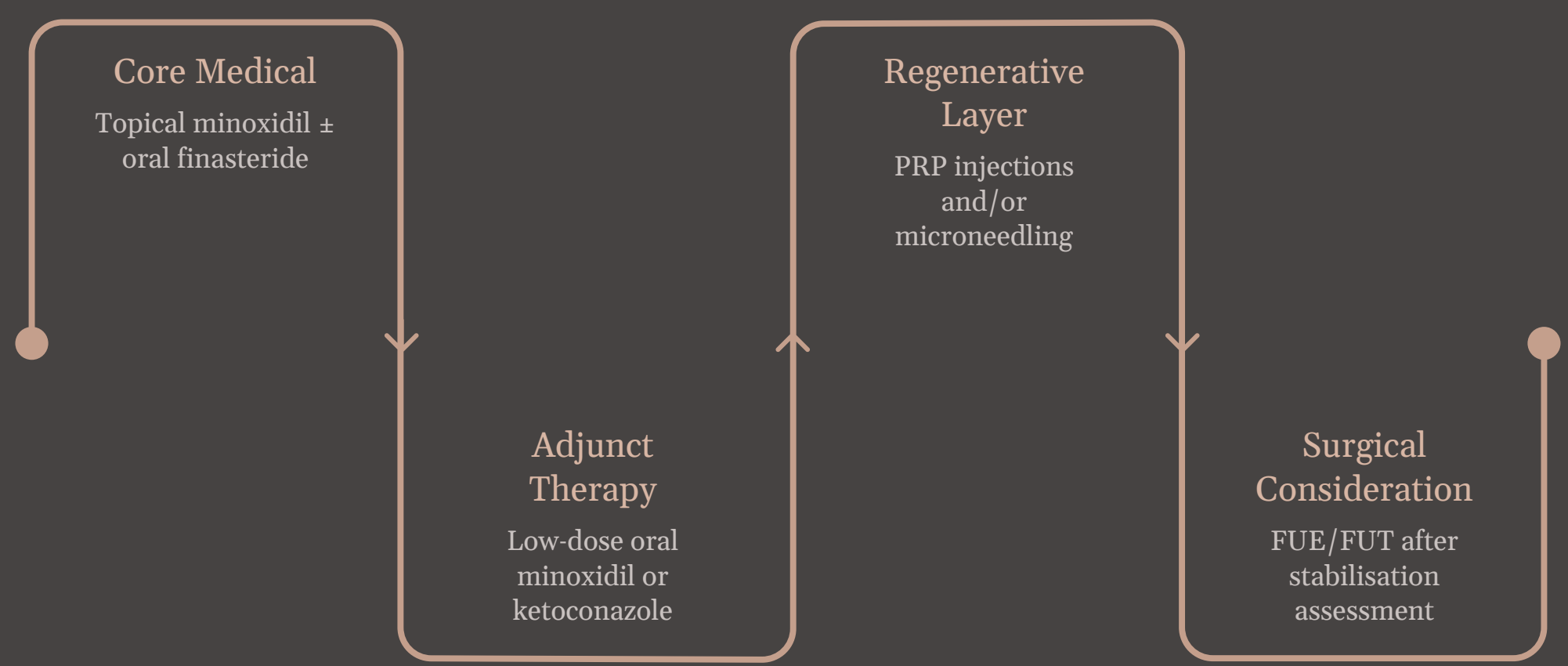

This four-step conceptual ladder represents a graduated approach where each step builds on the previous, with surgical candidacy assessed only after medical therapy has been optimised and disease stabilisation achieved or documented. Individual patient factors — cardiovascular history, libido concerns, sexual function history, systemic health, and patient preference — determine which agents are suitable and in what combination.

Agent	Mechanism	Evidence Grade in Male AGA	Key Counselling Points
Topical minoxidil 2–5%	Potassium channel opener; prolongs anagen, increases follicular calibre	Level 1 evidence; long-established efficacy and safety data	Initial shedding phase (telogen effluvium) in weeks 4–8 is expected and temporary; results require 4–6 months minimum to assess; long-term maintenance required
Low-dose oral minoxidil (0.625–2.5 mg/day)	Same mechanism as topical; systemic route improves adherence and bypasses topical tolerance issues	Growing evidence base; multiple RCTs; not FDA-approved for hair loss but widely used off-label	Cardiovascular assessment required; hypertrichosis (facial/body hair growth); fluid retention; contraindicated in cardiac disease; requires monitoring
Finasteride 1 mg/day	Type 2 5-alpha-reductase inhibitor; reduces scalp and serum DHT by approximately 60–70%	Level 1 evidence; FDA-approved for male AGA; landmark RCTs with 2–5 year follow-up data	Full treatment assessment requires 12 months; sexual side effects in 1–2% in trials (post-finasteride syndrome debated); contraindicated in those planning fatherhood in near term; discuss fully and document consent
Dutasteride 0.5 mg/day	Type 1+2 5-alpha-reductase inhibitor; reduces serum DHT by approximately 90–95%	RCT evidence supportive; approved for male AGA in some countries (Japan, Korea); off-label in US/UK	Greater DHT suppression than finasteride; potentially superior efficacy in resistant cases; longer half-life (5 weeks); similar side effect discussion applies with greater hormonal suppression profile
Ketoconazole shampoo 1–2%	Antifungal with mild anti-androgenic scalp effects; reduces Malassezia-driven inflammation	Moderate evidence as adjunct; not standalone first-line therapy	Useful adjunct particularly when seborrhoeic dermatitis coexists; reduces scalp inflammation that may compound shedding perception

8.5 Regenerative and Adjunctive Strategies in Male AGA

Platelet-Rich Plasma (PRP)

Platelet-rich plasma therapy has the strongest current clinical evidence base among regenerative adjunctive options for male AGA in routine practice. The biological rationale centres on the concentrated delivery of platelet-derived growth factors — including platelet-derived growth factor (PDGF), vascular endothelial growth factor (VEGF), transforming growth factor-beta (TGF-β), and insulin-like growth factor-1 (IGF-1) — to the perifollicular microenvironment, where they are hypothesised to stimulate dermal papilla cell proliferation, extend anagen duration, improve follicular vascularisation, and reduce perifollicular inflammation.

Clinical evidence supports PRP as producing meaningful improvements in hair density and calibre in patients with AGA when delivered as a series of treatments (typically three sessions at four-week intervals in induction, followed by maintenance at three to six monthly intervals). However, significant heterogeneity exists in preparation protocols, activation methods, platelet concentration targets, injection techniques, and treatment intervals across published studies, which limits direct comparison of results. PRP is best framed as an adjunctive treatment that enhances the results of core medical therapy, rather than as a substitute for finasteride or minoxidil in men with established AGA requiring disease control. Patients who decline or cannot tolerate oral medications may find PRP a partially compensating strategy, though the magnitude of benefit from PRP alone is generally less than combination medical therapy.

Microneedling and Emerging Therapies

Microneedling (percutaneous collagen induction therapy) using dermarollers or automated dermapens at depths of 0.5–1.5 mm has been investigated both as a standalone intervention and as an enhancement to topical minoxidil delivery. The biological rationale involves induction of local wound-healing cascades that upregulate growth factors, stimulate stem cell activation in the follicular bulge region, and transiently increase scalp vascular permeability to enhance topical penetration. Clinical trials using microneedling combined with minoxidil have shown superior results to minoxidil monotherapy in several randomised controlled trials, and the technique has achieved a reasonable evidence base as an adjunctive strategy. Adverse effects including post-procedure erythema, petechiae, and infection risk with poor sterile technique must be understood and managed.

Exosome-based therapies — delivering concentrated extracellular vesicles derived from mesenchymal stem cells or other cell sources, containing growth factor cargo and micro-RNA signals — represent a rapidly evolving frontier in hair regenerative medicine. Preclinical and early clinical data are promising, and the theoretical advantages over PRP include a more standardised and potent growth factor delivery without the variability of patient-specific platelet preparation. However, current regulatory status, manufacturing standardisation, and the clinical evidence base for exosomes in AGA remain in early stages. They should be positioned carefully for patients as emerging and investigational rather than established mainstream care, avoiding the marketing-driven overclaiming that is common in this space. Low-level laser therapy (LLLT) devices have also accrued a modest evidence base as adjuncts, particularly in patients reluctant to use pharmacological agents.

8.6 Surgical Candidacy and Long-Term Planning

A good transplant candidate is not simply a person who wants more hair and has sufficient donor supply for a single procedure. The physician must conduct a comprehensive multi-dimensional assessment of candidacy that accounts for the long-range trajectory of the disease as well as the state at the time of presentation. Surgical hair restoration without an integrated disease management plan can produce excellent initial results that become a long-term cosmetic problem as native hair continues to miniaturise around and behind the transplanted zones — a scenario that is entirely preventable with correct patient selection and counselling.

Age and Progression Risk

Younger men (under approximately 28–30 years) with active rapidly progressive disease pose the highest candidacy risk. Long-range pattern evolution in a 24-year-old is inherently unpredictable, and a hairline transplanted today may appear cosmetically inconsistent within five to seven years as disease progresses behind it. Age alone is not a disqualifying factor, but young age combined with rapid progression and family history of severe loss demands conservative hairline design and unconditional commitment to long-term medical therapy.

Donor Quality and Miniaturisation

Trichoscopic assessment of the donor zone is mandatory before any surgical planning conversation. Donor miniaturisation — evidence of anisotrichosis or reduced follicular unit density in the occipital and temporal safe-donor areas — is a significant contraindication to surgery, as grafts harvested from miniaturising follicles carry a materially elevated risk of progressive loss after transplantation ('shock loss' of pre-existing miniaturised hairs in the recipient zone and progressive loss of transplanted follicles that were already undergoing miniaturisation at the time of harvest).

Crown Demand and Resource Management

The crown is one of the most graft-intensive areas of the scalp to restore, and in a young man with progressive disease, crown coverage can consume the majority of available donor grafts without achieving lasting cosmetic stability. The physician must discuss openly with the patient that restoration of a cosmetically stable frontal frame is typically the superior long-term investment of finite donor resources, and that crown grafting in men with aggressive disease trajectory should be deferred until the pattern has substantially stabilised and donor supply assessment supports it without compromising future frontal maintenance needs.

Medical Commitment and Maintenance Willingness

Surgery is not a substitute for medical disease management; it is a complementary intervention that restores density in the redistributed donor pool. A patient who categorically refuses long-term medical maintenance therapy should be counselled frankly that surgical results will be gradually undermined by ongoing native hair loss in areas surrounding the transplanted zone. Willingness to engage with medical therapy is a candidacy criterion, not merely a recommendation.

8.7 Hairline Strategy, Crown Realism, and Failure Analysis

Hairline Design Principles

Hairline design is a clinical decision, not a purely aesthetic one, and must respect the patient's age, facial geometry, ethnicity, hair characteristics, probable future loss pattern, and available donor supply. A naturally positioned hairline that respects the principle of age-appropriate design — typically 7–9 cm above the glabella in a Caucasian male adult, with natural irregularity, temporal peaks, and micro-irregularity at the leading edge — will remain cosmetically consistent as the patient ages, while an artificially low, perfectly straight hairline designed to a youthful preference will appear increasingly incongruous over the following decade.

Ethnic considerations in hairline design are clinically meaningful: hairline position, temporal peak morphology, frontal tuft configuration, and hair growth direction vary systematically across ethnic groups and must be reflected in both design and surgical execution. The physician's role is to guide patients toward a result that will remain natural at 40 years and at 60 years, not only at the time of immediate post-operative assessment.

Structured Failure Analysis

When treatment — medical, regenerative, or surgical — appears to fail or underperform relative to the patient's and clinician's expectations, a structured failure analysis is more clinically useful than simply escalating or changing treatment empirically. The following questions form the core of a productive failure review:

- **Was the original diagnosis complete?** Could a coexisting telogen effluvium, alopecia areata, inflammatory component, or nutritional deficiency have been missed?
- **Was apparent progression actually shedding being confused with progression?** The initial telogen effluvium phase of minoxidil treatment, or disease-related shedding, may be perceived as treatment failure when it actually represents treatment initiation response.
- **Was adherence adequate and consistent?** Both topical minoxidil and oral 5-alpha-reductase inhibitors require months to years of consistent use before meaningful assessment of efficacy is possible.
- **Were patient expectations calibrated appropriately?** A patient expecting full regrowth from a stabilising treatment, or crown density improvement from frontal-targeted surgical restoration, will experience perceived failure despite objectively successful treatment.
- **Was the donor misread at surgical consultation?** Donor miniaturisation unrecognised pre-operatively may manifest as progressive graft loss post-operatively, appearing as surgical failure when it reflects an assessment failure.

Module 8: Clinical Pearls, Red Flags, and Assessment

🔵 Clinical Pearls

- Men rarely present with an isolated hairline problem; they present with a lifelong progressive androgenetic disease that requires long-range thinking, not reactive single-point interventions.
- Growth stimulation without concurrent DHT-lowering disease control will often disappoint in rapidly progressive AGA, particularly in young men with aggressive trajectories.
- A surgical plan should be defensible not just at the time of the consultation but ten years into the future — ask what the scalp will look like then, not only now.
- The initial shedding phase with minoxidil is a predictable and temporary pharmacological phenomenon, not evidence of treatment-induced progression.
- Donor miniaturisation assessment by trichoscopy is a mandatory component of surgical consultation, not an optional add-on.

🚨 Red Flags

- Diffuse thinning extending into the classically 'safe' occipital donor zone — suggests diffuse unpatterned alopecia or donor miniaturisation, both of which substantially alter management
- Rapid severe progression in a young patient not consistent with the family pattern — consider superimposed alopecia areata, inflammatory disease, or systemic cause
- Scalp symptoms or inflammatory trichoscopic signs not consistent with uncomplicated AGA — warrants separate investigation, not treatment acceleration
- Patient goals centred exclusively on a youthful juvenile hairline with explicit rejection of long-term medical maintenance — a major surgical candidacy concern requiring frank counselling

End-of-Module Assessment Prompts

1. Construct a staged, evidence-based treatment plan for a 28-year-old man with Norwood 3V AGA, strong family history, and early donor miniaturisation, justifying each component of the plan.
2. List and explain the factors that materially reduce male FUE transplant suitability.
3. Explain the distinction between disease stabilisation and hair regrowth as treatment goals, and describe how you communicate this distinction to a patient expecting significant regrowth from medical therapy.

MODULE 9

Female Pattern Hair Loss and Hormonal Hair Loss in Women

Female hair loss medicine requires substantially greater endocrine literacy, a broader differential diagnosis, more careful reproductive counselling, and greater psychological sensitivity than many male AGA consultations. The physician must integrate pattern recognition with menstrual history, metabolic assessment, thyroid function, nutritional status, postpartum physiology, perimenopausal and menopausal hormonal shifts, medication history, and the psychosocial dimensions of hair loss in women. The temptation to apply a simplified male AGA template to female presentations is a significant and common clinical error that leads to under-investigation, incorrect treatment, and poor patient outcomes.

1

Learning Objective 1

Recognise the diverse phenotypic presentations of female pattern hair loss and related hormonal hair-loss states, distinguishing them from other causes of female hair loss with overlapping presentations.

2

Learning Objective 2

Select targeted endocrine and laboratory investigations when clinically indicated, justified by specific phenotypic clues rather than universal reflexive ordering.

3

Learning Objective 3

Construct safe, evidence-based treatment plans in women of different ages and reproductive contexts, with particular attention to teratogenic risks, contraceptive reliability, and reproductive planning.

4

Learning Objective 4

Know when medical, regenerative, or surgical options are appropriate, insufficient, or contraindicated in female hair loss patients, and understand why long-term partnership rather than single-episode management defines best practice.

9.1 Phenotypes and Classification of Female Pattern Hair Loss

Female pattern hair loss is not a single visual stereotype, and framing it as merely 'the female equivalent of male AGA' substantially underrepresents its phenotypic diversity. The clinician should be comfortable recognising and describing the following distinct but overlapping presentations, any of which may occur in isolation or combination.

Central Part Widening (Ludwig Pattern)

Progressive widening of the central scalp part with relative preservation of the frontal hairline in many cases. This is the most commonly described female pattern and maps to Ludwig grades I–III. It may be subtle in early stages and becomes clinically apparent as diffuse crown attenuation. The frontal forelock is characteristically maintained, distinguishing this pattern from male AGA in many patients.

Frontal Accentuation Pattern

Some women display disproportionate frontal thinning, bitemporal recession, or Christmas-tree pattern frontal accentuation (Olsen pattern) in addition to or instead of predominant crown involvement. This pattern may be more strongly associated with androgen sensitivity and hyperandrogenic endocrine context, and requires attention to the clinical clues of androgen excess in the history and examination.

Diffuse Volume Reduction

Many women present primarily with reduced overall hair volume, increased scalp visibility in bright light, a thinner ponytail, and difficulty with styling density — without a clearly demarcated bald zone. This presentation is frequently dismissed or delayed in diagnosis because overt baldness has not occurred. Trichoscopy and careful part-line assessment are critical for diagnosis in this phenotype.

Classification scales serve different aspects of the phenotype: Ludwig grades (I–III) capture diffuse crown thinning severity; the Sinclair scale (1–5) provides an inclusive broad female classification; and the Olsen descriptors capture frontal accentuation and Christmas-tree patterning. No scale captures the full clinical picture, and all should be supplemented with a descriptive narrative documenting donor quality, calibre, colour contrast, rate of progression, and the patient's functional impact. Many women present later than men because the early change is a reduction in volume rather than overt baldness — ponytail reduction, scalp visibility in bright light, difficulty styling, and increased time spent concealing loss are diagnostically meaningful complaints that should be elicited specifically rather than waiting for them to be volunteered.

9.2 Hyperandrogenism, PCOS, and Endocrine Overlap

The Hyperandrogenic FPHL Subset

Not all female patterned loss is hyperandrogenic in its aetiology, and not all women with FPHL require androgen assessment, as discussed in Module 7. However, a clinically important subset of women present with FPHL in the context of demonstrable or suspected androgen excess, and this subset requires a fundamentally different investigative and treatment approach. The clinical clue of hyperandrogenism in a woman with hair loss should be actively sought, not passively waited for.

Polycystic ovary syndrome (PCOS) is the most common endocrine cause of hyperandrogenaemia in women of reproductive age, with a prevalence of approximately 8–13% in this demographic. PCOS is defined by the Rotterdam criteria as requiring two of three features: oligo/anovulation, clinical or biochemical signs of hyperandrogenaemia, and polycystic ovarian morphology on ultrasound. Women with PCOS may present with any combination of oligomenorrhoea, infertility, severe cystic acne, generalised or regional hirsutism, weight gain with central distribution, insulin resistance, and androgenetic alopecia. The scalp may in some women be the most visible and distressing androgen-sensitive site of the syndrome, and hair loss may precede the overt manifestation of other PCOS features by several years.

Follicular Sensitivity vs. Circulating Androgens

A clinically important and often poorly understood principle is that patterned hair loss can occur — and can be androgen-mediated — in women with androgens entirely within the conventional laboratory reference range. This apparent paradox reflects the fact that androgenetic alopecia depends not only on the circulating concentration of androgens but on the local amplification of androgenic signalling within susceptible follicles. The density of intrafollicular 5-alpha-reductase activity, androgen receptor expression, and intrafollicular androgen metabolism determines the effective androgenic stimulus at the follicular level, independent of the circulating androgen level measured in peripheral blood.

This principle is of major clinical importance because it means that a 'normal' testosterone result in a woman with FPHL does not exclude androgen-mediated miniaturisation, does not contraindicate anti-androgen treatment, and should not be used as evidence that the hair loss is unrelated to androgen physiology. The physician must explain this distinction to the patient, who typically expects that if androgens are 'normal,' the hair loss cannot be hormonal in nature — a misconception that, if uncorrected, leads to rejection of anti-androgen treatment that might substantially benefit follicular health.

9.3 Thyroid Disease, Iron, Nutrition, and Diffuse Shedding Overlap

In clinical practice, women presenting with hair loss frequently have mixed aetiologies rather than a single pure cause. The most common clinical scenario encountered in a busy specialist practice is a woman with an underlying baseline of FPHL who is simultaneously experiencing a telogen effluvium triggered by one or more modifiable systemic factors. Treating only the FPHL or only the telogen effluvium will produce inferior results compared with identifying and managing all contributing components simultaneously.

Iron Deficiency and Iron-Deficiency Anaemia

Iron deficiency — with or without frank anaemia — is among the most commonly identified modifiable contributors to female hair loss. The mechanism is not fully elucidated but is hypothesised to involve impaired mitochondrial energy availability in the rapidly dividing follicular matrix cells of anagen follicles, which are among the most metabolically demanding cells in the body. The clinical history should actively include menstrual flow volume (heavy periods are the leading cause of iron depletion in premenopausal women), dietary adequacy of haem iron, vegetarian or vegan dietary patterns, gastrointestinal symptoms suggesting malabsorption, and any history of blood donation, surgical blood loss, or chronic medical conditions associated with iron depletion. Both ferritin and iron saturation should be reviewed in context, and treatment of confirmed deficiency with appropriate iron supplementation or investigation of the cause of deficiency is a standard component of female hair loss management.

Thyroid Dysfunction

Both hypothyroidism and hyperthyroidism can produce diffuse telogen shedding, reduced hair calibre, changes in hair texture, and outer eyebrow thinning. Thyroid-related hair loss is often underappreciated because the hair loss may predate the overt clinical thyroid diagnosis by several months, and mild subclinical hypothyroidism may produce sufficient follicular perturbation to drive meaningful shedding without the full clinical syndrome of hypothyroidism. TSH should be included in the initial workup of any woman with diffuse shedding of unexplained cause, and clinically abnormal results should be referred for thyroid-specific management rather than empirically treated by the trichologist. Once thyroid function is normalised, recovery of hair loss typically follows over 6–12 months but may be incomplete if FPHL was the underlying substrate.

Nutritional Deficiency and Restrictive Diet

The hair follicle is nutritionally demanding and disproportionately sensitive to abrupt caloric restriction, macronutrient depletion, and micronutrient deficiency. Crash dieting, prolonged caloric restriction, restrictive eating disorders (anorexia nervosa, orthorexia), very-low-calorie ketogenic diets, and the immediate post-bariatric surgery period are all well-recognised contexts for severe and sometimes prolonged telogen effluvium. The history should explicitly address recent dietary changes, weight change over the preceding six to twelve months, and any history of bariatric surgery, inflammatory bowel disease, coeliac disease, or other malabsorption syndromes. Protein adequacy, not just micronutrient levels, is an often-overlooked aspect of nutritional hair loss assessment.

9.4 Reproductive Life Stage: Postpartum, Perimenopause, and Menopause

Postpartum Hair Loss

Postpartum telogen effluvium is physiologically universal to a variable degree: the sustained elevation of oestrogen during pregnancy prolongs the anagen phase and prevents the normal follicular cycling that would produce routine shedding. Following delivery, oestrogen withdrawal initiates a synchronised telogen shift across a substantial proportion of scalp follicles, producing a wave of shedding that typically peaks between 3 and 6 months postpartum. In women without underlying FPHL, this process is self-limited and complete within 12 months in most cases.

However, postpartum shedding may unmask or accelerate underlying female pattern hair loss that was previously clinically inapparent during the hair-conserving oestrogen-dominant state of pregnancy. This is a particularly important distinction for clinical management: a woman experiencing diffuse shedding at four months postpartum who then plateaus with persistently reduced density 18 months after delivery has not continued to experience postpartum effluvium — she has experienced the natural resolution of the effluvium revealing the FPHL that was masked during pregnancy. The management of the FPHL component requires the same approach as FPHL at any other life stage, with reproductive planning and contraception considered before initiating anti-androgen therapy.

Perimenopause and Menopause

The perimenopausal transition — typically beginning in the mid-forties with a mean duration of four to seven years before the final menstrual period — is characterised by declining and increasingly erratic ovarian oestrogen production, relative progestogen insufficiency, and rising gonadotropins. The net effect on hair is multifactorial: declining oestrogens reduce the hair-conserving effects on the follicular cycle; the relative shift in the oestrogen-androgen ratio may increase effective androgenic stimulation of susceptible follicles even without a change in absolute androgen production; changes in sebum production may alter scalp microbiome and inflammation; and hair shaft quality — including reduced calibre, altered texture, and reduced tensile strength — may change independently of follicular density.

Menopause should be recognised as a significant inflection point for FPHL progression in genetically susceptible women, and the clinical narrative must clearly distinguish physiological shedding changes (which are expected, time-limited in their acute phase, and partially reversible with hormonal support), chronic progressive follicular miniaturisation (FPHL, which is not reversible but may be slowed), and reversible contributing factors such as iron depletion, thyroid change, sleep disruption, and the psychological stress of the menopausal transition itself. These phases are emotionally laden for many women. Clinical language must be both precise and compassionate.

9.5 Trichoscopy and Biopsy in Female Patients

Trichoscopy in female hair loss patients serves the same fundamental comparative and diagnostic role as in males, but the differential diagnosis is broader and the diagnostic challenge is frequently greater. The most clinically useful trichoscopic assessments in women are: comparison of frontal/central zone against occipital control for shaft diameter diversity and follicular unit count; assessment of part-line width and density under dermoscopic magnification; evaluation of peripilar sign in patterned zones; and examination of the frontal hairline margin for perifollicular erythema or scale that might suggest frontal fibrosing alopecia in a woman being evaluated for apparent FPHL.

FPHL vs. Chronic Telogen Effluvium

Chronic telogen effluvium (CTE) can closely mimic FPHL clinically. Trichoscopy in CTE typically shows relative preservation of shaft diameter homogeneity across all scalp zones, with diffuse density reduction affecting occipital scalp comparably to frontal scalp. In FPHL, anisotrichosis is patterned in the frontal/central zones with relative occipital sparing. Intermediate presentations reflecting mixed disease are common.

Diffuse Alopecia Areata

In women, diffuse alopecia areata (alopecia areata incognita) may very closely mimic both CTE and FPHL. Yellow dots across all zones including occipital, tapered hairs, and uniform rather than patterned anisotrichosis are key differentiating trichoscopic features. This distinction is critical because treatment is fundamentally different and topical/oral minoxidil and anti-androgens will not address an immune-mediated process.

Frontal Fibrosing Alopecia

FFA is increasingly prevalent in postmenopausal women. The classic trichoscopic features — perifollicular erythema and scale at the hairline advancing margin, loss of follicular openings in the affected band, and absence of vellus hairs at the hairline — must be actively sought in any woman with apparently straightforward frontotemporal recession. Misdiagnosis as FPHL leads to inappropriate management and unnecessary disease progression.

When to Biopsy in Women

Biopsy is not routine in straightforward FPHL with consistent clinical and trichoscopic features. It becomes important in diagnostically mixed cases, when inflammatory disease is suspected or cannot be excluded trichoscopically, when treatment response is absent or atypical, or when the patient has concurrent systemic autoimmune disease. Site selection follows the same principles as outlined in Module 7.

9.6 Medical Treatment Framework in Women

Treatment planning in women with hair loss requires integration of evidence-based pharmacology with the specific reproductive context, safety profile, and monitoring requirements of each agent. The appropriate treatment plan for a 28-year-old woman with FPHL who is sexually active without reliable contraception differs fundamentally from the plan for a 55-year-old postmenopausal woman with the same clinical presentation.

Agent	Mechanism	Reproductive Considerations	Key Monitoring and Counselling
Topical minoxidil 2–5% (solution or foam)	Potassium channel opener; prolongs anagen, improves calibre	Avoid in pregnancy and breastfeeding; not a teratogen at topical doses but systemic absorption occurs and safety data in pregnancy are insufficient	Initial shedding phase expected and temporary; 4–6 months minimum to assess response; lifelong maintenance required for sustained benefit
Low-dose oral minoxidil (0.625–1.25 mg/day in women)	Same mechanism, systemic route	Same precautions as topical; lower dose range used in women; not approved for hair loss but widely used off-label	Hypertrichosis (facial/body hair growth) is the most common cosmetically significant adverse effect; fluid retention, orthostatic hypotension; cardiovascular assessment required
Spironolactone (50–200 mg/day)	Aldosterone antagonist with anti-androgen effects via androgen receptor blockade and mild reduction of adrenal androgen synthesis	**Teratogenic to male fetuses**; must not be used in pregnancy; reliable contraception is mandatory in women of reproductive potential; discuss and document thoroughly	Monthly potassium monitoring initially (hyperkalaemia risk particularly if other medications); menstrual irregularity common; diuresis; anti-hypertensive effect; avoid in renal impairment
Finasteride 2.5–5 mg/day (off-label in women)	5-alpha-reductase inhibitor type 2	**Highly teratogenic to male fetuses** (genital malformation); absolute contraindication in pregnancy and women of reproductive potential without highly reliable contraception; most commonly used in postmenopausal women	Liver function monitoring periodically; mood effects; off-label use requires specific informed consent documentation
Dutasteride (off-label, limited use in women)	Type 1+2 5-alpha-reductase inhibitor	Same teratogenic risk as finasteride; even more limited safety data in women; use is specialist-level and off-label only	Reserved for postmenopausal women or those with irreversibly assured contraception; monitor liver function
Combined oral contraceptive pill (low-androgenic formulation)	Suppresses LH/FSH and ovarian androgen production; raises SHBG, reducing free androgen bioavailability	May improve FPHL in hyperandrogenic context; choice of progestogen matters — anti-androgenic progestogens (drospirenone, cyproterone acetate, chlormadinone) preferred; androgenic progestogens may worsen AGA	Standard OCP monitoring and contraindications apply; discuss thrombotic risk; not suitable in smokers over 35 years

9.7 Regenerative Medicine and Female-Specific Surgical Thinking

PRP and Emerging Regenerative Options

Platelet-rich plasma can be a clinically useful adjunct in female pattern hair loss, particularly where the treatment goal is calibre support, density optimisation, and improvement in shed hair count rather than restoration of genuinely absent follicles. The evidence base for PRP in FPHL mirrors that in male AGA — a growing number of well-designed randomised controlled trials support meaningful improvements in hair density and calibre, with the best results achieved when PRP is used in combination with core medical therapy rather than as a monotherapy. In women who decline or cannot tolerate oral anti-androgen therapy or minoxidil, PRP may represent a partially compensating strategy with a favourable safety profile and no reproductive contraindications, making it a practical option for women of reproductive age or those who are pregnant (postpartum PRP is sometimes discussed, though the evidence during active pregnancy is absent).

Exosome therapies and low-level laser therapy (LLLT) occupy the same 'adjunctive/emerging' category in female FPHL as in males. Exosomes specifically should be positioned for patients as investigational and not yet standardised for mainstream clinical practice, while LLLT has a modest but real evidence base that supports its use as a safe and accessible adjunct, particularly for patients who prefer non-pharmacological strategies. Nutraceutical supplements — including marine collagen, biotin where deficiency is confirmed, and omega-fatty-acid formulations — have limited independent evidence for FPHL specifically but may support overall hair health in the context of confirmed nutritional insufficiency.

Surgery in Female Hair Loss Patients

Hair transplantation in women requires a markedly different assessment framework from the male surgical consultation. Women present much less commonly as surgical candidates because the majority have diffuse unpatterned thinning that affects the entire scalp rather than a clear stable donor zone — and transplanting hairs from a thinning donor into a thinning recipient is likely to produce progressive graft loss and a worsened cosmetic outcome. The fundamental prerequisite for female surgical candidacy is confirmation of a genuinely stable and dense donor zone with trichoscopic evidence that follicular miniaturisation is confined to the patterned androgenetically susceptible area and is not affecting occipital and temporal donor follicles.

Women with confirmed FPHL in whom the donor is trichoscopically stable, who have achieved medical stabilisation, who have realistic expectations, and who understand the limitations of transplantation as a redistribution rather than multiplication of follicles, may be excellent surgical candidates — particularly for targeted augmentation of the frontal frame, part-line enhancement, or restoration of temporal density. Active inflammatory scalp disease or diffuse ongoing miniaturisation are absolute contraindications to surgery and should result in deferral of any surgical planning until disease stability is established.

Long Hair FUE (harvesting and transplanting hairs without shaving the donor zone) and zone-shave strategies can significantly improve surgical acceptability for women who are psychologically unwilling to shave the donor area. These techniques require additional surgical skill and planning but are increasingly considered standard options in female hair restoration surgery. The physician must ensure that expectations for Long Hair FUE — including the transient shedding of transplanted shafts in the weeks following surgery before regrowth begins — are thoroughly and honestly communicated pre-operatively.

9.8 Communication, Psychology, and Long-Term Partnership

Hair loss in women is not simply a cosmetic concern — it is a condition that frequently carries a disproportionate psychological burden of shame, concealment, social anxiety, reduced self-confidence, and impaired quality of life, dimensions that substantially exceed those reported for comparable hair loss severity in men across multiple validated quality-of-life studies. The physician must not mistake a calm, composed, or minimising presentation for low psychological impact. Many women have already normalised their distress, concealed it from family members, and adapted their lives around managing the hair loss before they present for medical help. The decade between first noticing the loss and first seeking specialist help is not unusual.

Communication Principles

Language matters materially in the female hair loss consultation. Phrases such as 'this is just normal female thinning' or 'it will settle down after a few months' without supporting clinical reasoning can dismiss genuine chronic disease and damage the therapeutic relationship. Conversely, clinical language that accurately names the diagnosis — including the mixed and multifactorial nature of most presentations — combined with a structured, optimistic, and realistic management plan empowers the patient and builds appropriate engagement with treatment.

The distinction between physiological shedding (temporary, recoverable), chronic patterned miniaturisation (progressive but manageable with treatment), and reversible contributing factors (treatable and improvable) should be clearly explained. Most women benefit from having these three categories named and separated, as the conflation of all hair loss into a single undifferentiated problem generates helplessness, whereas understanding the structure of the problem creates agency. This communication framework also sets realistic expectations: the reversible components may resolve substantially within months; the FPHL component will require long-term management.

Framing Long-Term Management

Because female hair loss is frequently chronic, multifactorial, and lifelong in its pattern component, the physician should explicitly frame management as longitudinal optimisation rather than one-off rescue. Setting this expectation from the first consultation prevents the demoralisation that occurs when a patient receives a course of treatment, experiences initial improvement, but then observes gradual re-thinning after stopping treatment — and concludes that treatment has 'stopped working' rather than that the chronic disease requires continuous management.

Annual or biannual follow-up consultations with comparative photography should be built into the management plan as a default, not offered only when the patient re-presents with concern. Proactive monitoring demonstrates clinical investment in the longitudinal outcome and allows early identification of treatment inadequacy, disease progression requiring therapy escalation, or new contributing factors that have emerged in the interim. In women approaching perimenopause on a treatment plan initiated in their thirties, the management strategy should be proactively reviewed at the perimenopausal transition, as hormonal shifts may alter both the pace of FPHL and the reproductive safety context of existing treatments.

Module 9: Clinical Pearls, Red Flags, and Assessment

🔵 Clinical Pearls

- Female patterned loss almost always coexists with one or more shedding disorders; mixed aetiology is the rule rather than the exception in specialist practice, and all contributing components should be identified and addressed simultaneously.
- Normal serum androgens do not exclude hormonally responsive follicular miniaturisation; the intrafollicular androgenic environment is determined by local enzyme activity and receptor expression, not only peripheral blood androgen concentration.
- Treatment safety and reproductive planning are integral components of the clinical consultation in women of reproductive potential, not afterthoughts or optional add-ons.
- The decision to defer surgery pending medical stabilisation protects the patient from a potentially lifelong cosmetic problem and should be communicated as a clinical act of care, not a refusal.
- Many women have lived with significant hair-related distress for years before seeking help; the physician's first consultation often carries substantial weight in either validating or dismissing an experience the patient has previously been told to accept.

🚨 Red Flags

- Rapid diffuse reduction in density with concurrent eyebrow or body hair loss — broaden the differential urgently; exclude systemic, autoimmune, and alopecia areata-spectrum causes
- Marked hirsutism, virilisation, infertility, or severe menstrual disturbance — androgen-secreting tumour must be excluded if testosterone is significantly elevated
- Scalp pain, perifollicular scale, or loss of ostia — suspected cicatricial disease requires biopsy and specialist inflammatory management; do not treat as FPHL
- Request for surgical consultation before stabilisation of active diffuse loss — surgery is contraindicated and deferral is clinically mandatory
- Anti-androgen prescription in a woman of reproductive potential without confirmed reliable contraception and documented informed consent — a significant prescribing safety failure

End-of-Module Assessment Prompts

1. Outline a structured investigative and management plan for a 34-year-old woman presenting with central part widening, moderate acne, and oligomenorrhoea, justifying each clinical decision.
2. Explain the trichoscopic and clinical features you would use to differentiate chronic telogen effluvium from female pattern hair loss in a woman presenting with diffuse thinning of 18 months' duration.
3. Describe a safe, evidence-based treatment strategy for a 29-year-old woman with FPHL who is not currently seeking pregnancy but has not excluded it as a future possibility.

VOLUME 2 SUMMARY

Integrating the Diagnostic Core: Volume 2 Summary

By the end of Volume 2, the learner should be capable of moving from an undifferentiated hair loss complaint to a disciplined, structured diagnostic impression — constructing a differential diagnosis based on pattern recognition, symptom analysis, and trichoscopic findings; selecting proportionate laboratory investigations based on phenotype and probability; identifying when scalp biopsy is indicated and how to maximise its diagnostic yield; and constructing evidence-based initial management plans for both male and female pattern hair loss within the specific clinical and reproductive context of each individual patient. This is the diagnostic and clinical core on which the therapeutic, regenerative, and surgical volumes of the academy depend.

The five modules in this volume are deliberately sequenced to build clinical competence in a logical progression: examination precedes trichoscopy, trichoscopy informs investigation strategy, investigation logic grounds diagnosis, and the two pattern hair loss modules apply all preceding skills to the commonest clinical presentations. This architecture reflects how expert clinical reasoning actually operates — not as a sequence of isolated tasks but as an integrated, iterative process in which each layer of assessment informs and refines the layers around it.

Cross-Module Diagnostic Framework

The following integrative framework synthesises the key decision logic across all five modules of Volume 2. It is intended as a reference structure for clinical reasoning — a scaffold to ensure that no critical diagnostic step is omitted and that each layer of assessment contributes meaningfully to the final clinical impression.

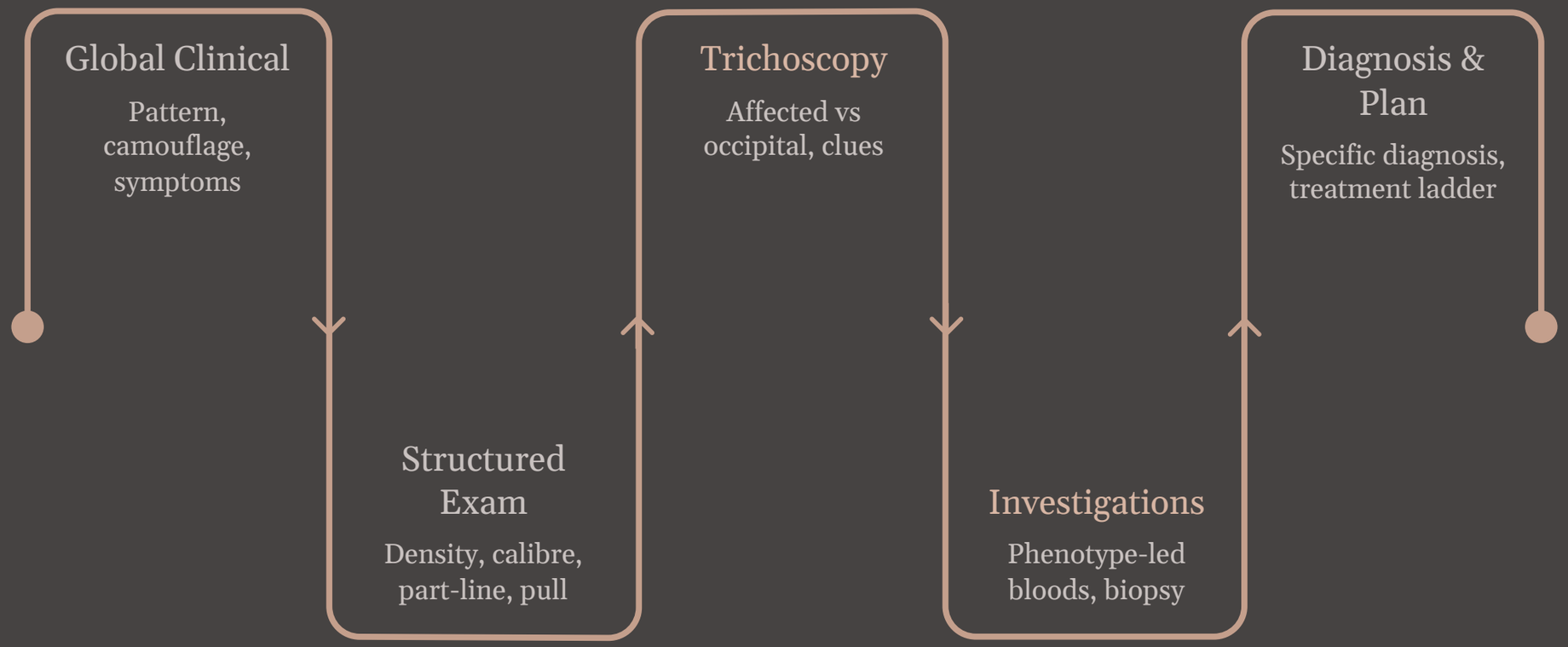

This five-stage framework is not a rigid protocol but a disciplined habit of thought. Expert practitioners move fluidly between stages — trichoscopy may immediately redirect the clinical impression established during examination, or a laboratory result may prompt re-examination of a previously assessed clinical feature. What distinguishes physician-level diagnostic skill is not the ability to follow a linear checklist, but the capacity to hold multiple diagnostic hypotheses simultaneously and update them systematically as each layer of information is acquired.

Comparative Diagnostic Summary: Key Differentials in Pattern Hair Loss

The following table provides a rapid-reference comparison of the principal conditions encountered across Modules 5–9. It is designed to support differential diagnosis rather than replace the detailed reasoning covered in each module. No single row should be read as a complete diagnostic algorithm; it summarises the most discriminating features for each condition in the appropriate clinical context.

Condition	Distribution Pattern	Trichoscopic Hallmarks	Key Investigations	Biopsy Needed?	First-Line Treatment Direction
Male AGA	Frontotemporal, crown; occipital spared	Anisotrichosis, peripilar sign, reduced hairs/unit in patterned zones	Usually clinical; trichoscopy sufficient in typical presentation	Rarely; if atypical or mixed	Topical/oral minoxidil + finasteride; PRP adjunct; surgical candidacy assessment
Female Pattern Hair Loss	Central part widening, crown attenuation, ± frontal accentuation; frontal hairline variably spared	Patterned anisotrichosis frontal > occipital; peripilar sign; part-line widening under dermoscopy	Iron, thyroid, ± androgen panel if hyperandrogenic features present	In diagnostically mixed or atypical cases	Topical/oral minoxidil; spironolactone in suitable women; anti-androgen where indicated
Chronic Telogen Effluvium	Diffuse, no patterned predilection; frontal shedding common but occipital equally affected	Relative shaft diameter homogeneity; short regrowing hairs; no anisotrichosis in patterned zones	Iron, ferritin, thyroid, FBC, B12/folate, inflammatory markers, medication review	If diagnosis uncertain or non-responsive to trigger removal	Identify and treat trigger; nutritional optimisation; support and monitoring
Alopecia Areata (patchy)	Discrete patches; any scalp zone; may affect eyebrows, lashes, body hair	Yellow dots, black dots, exclamation mark hairs, tapered hairs in active patches	Usually clinical + trichoscopic; autoimmune screen if indicated; thyroid	Atypical presentations or diagnostic uncertainty	Intralesional or topical corticosteroids; systemic immunotherapy for extensive disease; JAK inhibitors in severe/refractory
Diffuse Alopecia Areata (Incognita)	Diffuse, mimics CTE or FPHL; occipital scalp affected as much as frontal	Yellow dots across all zones including occipital; tapered hairs; no patterned anisotrichosis	Autoimmune screen; thyroid; trichoscopy-guided biopsy if diagnosis remains uncertain	Frequently required for definitive diagnosis	Systemic immunotherapy; JAK inhibitors in suitable patients; avoid minoxidil monotherapy without immune management
Lichen Planopilaris / FFA	LPP: crown/mid-scalp progressive scarring. FFA: bandlike frontotemporal hairline recession ± eyebrow loss	Perifollicular erythema and scale, loss of ostia at advancing margin, white structureless areas in burnt-out zones	Biopsy is frequently required; autoimmune screen; thyroid in FFA; liver function before systemic agents	Yes — mandatory for definitive diagnosis and to guide systemic treatment	Topical/intralesional corticosteroids; hydroxychloroquine; tetracyclines; dutasteride in FFA; systemic immunosuppression in progressive LPP
Folliculitis Decalvans	Central scalp predominantly; progressive scarring with tufting and purulent folliculitis	Tufting (polytrichia), pustules, perifollicular erythema, crusting, loss of ostia	Bacterial swab (Staphylococcus aureus commonly cultured); biopsy; full blood count	Yes — confirms diagnosis and guides management	Prolonged antibiotic therapy (rifampicin + clindamycin protocol); topical antiseptics; specialist dermatology management

Volume 2 Knowledge Architecture: Building Toward Advanced Practice

Volume 2 occupies a specific and essential position in the broader HLI/IIIOHR Academy curriculum. It represents the bridge between the foundational science of Volume 1 — which establishes hair biology, follicular cycling, miniaturisation mechanisms, and basic classification — and the advanced therapeutic, regenerative, and surgical volumes that follow. Without the clinical diagnostic competence developed in this volume, subsequent treatment knowledge risks being applied imprecisely or to incorrectly identified diagnoses, producing avoidable treatment failures and patient harm.

Volume 1: Foundations

Hair biology, follicular cycling, miniaturisation mechanisms, basic histology, classification systems, and introduction to hair loss categories.

Volume 2: Diagnosis (This Volume)

Clinical examination, trichoscopy, investigations and biopsy logic, male AGA, and female pattern hair loss — the diagnostic core of specialist practice.

Volume 3: Medical and Regenerative Therapy

Advanced pharmacological treatment, regenerative medicine protocols, combination strategies, treatment monitoring, and management of treatment failure.

Volume 4: Surgical Hair Restoration

FUE and FUT technique, donor management, recipient design, hairline strategy, complication management, and surgical outcomes assessment.

Volume 5: Advanced and Specialist Topics

Scarring alopecias, alopecia areata spectrum, paediatric hair loss, systemic disease and hair, emerging technologies, and global practice considerations.

The competencies developed across Modules 5–9 are not sequential skills that become redundant once the next module is mastered — they are recursive and mutually reinforcing. The examination skills of Module 5 become more powerful in the context of trichoscopy; the trichoscopic language of Module 6 becomes more precise when grounded in investigation logic; the investigation framework of Module 7 becomes more targeted when the clinical phenotypes of Modules 8 and 9 are deeply understood. Advanced trichology practice is the capacity to integrate all of these layers simultaneously in a single clinical encounter, arriving at a diagnostic impression and management plan that is both individually tailored and evidence-grounded.

LMS Integration and Self-Assessment Guide

This volume is designed to support both self-directed study using the academy manual and structured online learning delivered through the IIIOHR LMS platform at iiohr.com. The following guide maps each module's content to the LMS learning activities and provides a structured approach to self-assessment and competency verification.

Self-Assessment Recommendations

For each module, the learner should complete the following self-assessment sequence before advancing to the next module:

1. **Pre-reading reflection:** Before studying the module, write a brief summary of what you currently know about the topic. This activates prior knowledge and establishes a baseline for measuring learning gain.
2. **Active reading:** As you read, annotate clinical pearls, red flags, and decision points. Build your own diagnostic reasoning map for each condition covered.
3. **End-of-module assessment prompts:** Answer each assessment prompt in writing before reviewing model answers. Writing forces retrieval practice, which is the most effective consolidation strategy for clinical knowledge.
4. **Case application:** Identify a real or simulated clinical case that illustrates the key learning from each module and apply the diagnostic frameworks taught. Reflect on where your reasoning would have differed before studying the module.
5. **Peer discussion:** Where possible, discuss assessment prompt answers with a peer or mentor. Articulating clinical reasoning aloud or in dialogue identifies gaps that solitary study may not reveal.

LMS Platform Mapping

Module	Associated LMS Activities
Module 5: Clinical Examination	Practical consultation lesson videos; examination technique demonstrations; structured observation checklists; clinical photography protocol templates
Module 6: Trichoscopy	Trichoscopy image atlas with annotated cases; pattern recognition quiz with immediate feedback; biopsy site selection case exercises; comparative dermoscopy exercises (normal vs. pathological)
Module 7: Investigations and Biopsy	Phenotype-to-investigation pathway case studies; laboratory result interpretation exercises; biopsy indication decision trees; histopathology image library with clinical correlation exercises
Module 8: Male AGA	Norwood staging interactive case bank; treatment ladder construction exercises; surgical candidacy assessment cases; failure analysis structured reflection exercises
Module 9: Female Hair Loss	Female phenotype classification image bank; reproductive counselling scenario exercises; mixed aetiology case reviews; endocrine workup interpretation exercises; long-term management planning cases

Learners who complete all five modules with satisfactory performance on LMS assessments and demonstrate applied clinical reasoning through case-based exercises will be eligible for the Volume 2 competency certification through the IIIOHR Advanced Trichology Academy.

Glossary of Key Terms: Volume 2

The following glossary provides precise clinical definitions for the principal terms used across Modules 5–9. Understanding the exact meaning of these terms is essential for accurate clinical communication, examination performance, and interpretation of clinical literature.

Term	Definition
Anisotrichosis	The coexistence of hair shafts of significantly different diameters within a single follicular unit or across adjacent follicular units in the same scalp zone. Quantified as >20% diameter variation in some research protocols. The hallmark trichoscopic finding of androgenetic miniaturisation.
Peripilar sign	A brown perifollicular halo of up to 1 mm diameter surrounding follicular ostia in pattern-loss-affected scalp zones. Reflects perifollicular lymphocytic infiltration and fibrosis associated with progressive miniaturisation. Present in approximately 60–70% of AGA patients.
Yellow dots (trichoscopy)	Enlarged follicular openings filled with keratinous and/or sebaceous material, appearing as yellow or yellow-white circles under dermoscopy. The most consistently present trichoscopic sign of alopecia areata across all skin phototypes; also seen in androgenetic alopecia in some patients.
Exclamation mark hairs	Short broken hairs with a narrowed, depigmented proximal shaft widening to normal calibre distally, resembling the punctuation mark. Indicate structural shaft weakness from perifollicular immune attack. Highly specific for active alopecia areata.
Cadaverised hairs (black dots)	Residual pigmented hair shaft fragments at or below the follicular ostium surface, resulting from complete anagen hair breakage in the context of immune-mediated anagen arrest. Marker of active alopecia areata disease. More visible in darker hair colour phototypes.
Miniaturisation	The progressive reduction in follicular volume, anagen phase duration, and resultant hair shaft diameter driven by androgen receptor activation in susceptible dermal papilla cells. The fundamental biological process of androgenetic alopecia. Reversible in early stages; increasingly irreversible with prolonged disease duration.
Terminal-to-vellus ratio	The histologic ratio of terminal-calibre follicles to vellus-calibre follicles in a standardised scalp biopsy section. In normal scalp, the ratio is approximately 7:1. In established androgenetic alopecia, the ratio is reduced. Quantified most accurately on horizontal biopsy sections.
Tufting (polytrichia)	The emergence of multiple hair shafts (often 6–20 or more) from a single enlarged follicular ostium, resulting from follicular destruction and pathological fusion of adjacent follicular units within a fibrous scar matrix. Characteristic of folliculitis decalvans and dissecting cellulitis.
Telogen effluvium	A non-scarring diffuse shedding disorder characterised by premature shift of anagen follicles into the telogen (resting) phase in response to a systemic trigger, resulting in synchronised shedding typically peaking 2–4 months after the trigger. May be acute (self-limiting) or chronic (>6 months duration).
Cicatricial (scarring) alopecia	A group of hair loss disorders characterised by permanent destruction of the hair follicle and its stem cell niche, resulting in irreversible hair loss and replacement of the follicular apparatus with fibrous tissue. Clinically identified by loss of follicular openings, atrophy, and absence of follicular regrowth.
Anagen effluvium	Rapid diffuse hair loss caused by acute damage to the actively dividing cells of the hair matrix during the anagen phase. Most commonly caused by chemotherapy agents and ionising radiation. Distinguished from telogen effluvium by its rapid onset (days to weeks after trigger), completeness of loss, and anagen root morphology.
Norwood-Hamilton classification	The most widely used staging system for male androgenetic alopecia, describing seven primary stages (I–VII) with substages reflecting the progressive topographic involvement of the frontotemporal angles, frontal forelock, mid-scalp, and crown. Provides a standardised communication and surgical planning framework.
Ludwig classification	A three-grade classification system for female pattern hair loss describing diffuse crown thinning severity: Grade I (minimal widening visible on parting), Grade II (pronounced widening with visible scalp), Grade III (full transparent scalp visible in crown with preserved frontal hairline).
5-alpha-reductase	The enzyme responsible for the intrafollicular conversion of testosterone to dihydrotestosterone (DHT). Type 1 isoform is expressed predominantly in sebaceous glands, skin, and liver; type 2 isoform is expressed predominantly in hair follicle dermal papilla and outer root sheath cells. The pharmacological target of finasteride (type 2 selective) and dutasteride (type 1 and 2 dual inhibitor).
Sex hormone binding globulin (SHBG)	A liver-synthesised glycoprotein that binds testosterone and oestradiol in the bloodstream, reducing their bioavailability to target tissues. Low SHBG increases the free fraction of testosterone, elevating androgenic stimulus to susceptible follicles even with normal total testosterone. Reduced by insulin resistance, obesity, and certain progestogens.
Frontal fibrosing alopecia (FFA)	A primary cicatricial alopecia clinically presenting as a band-like recession of the frontal and temporal hairline, often with associated eyebrow and eyelash loss. Trichoscopically characterised by perifollicular erythema and scale at the advancing margin with loss of ostia in the established alopecia band. Predominantly affects postmenopausal women; increasing incidence in men also recognised.

Volume 2: Recommended Further Reading and Reference Frameworks

The following reference categories represent the principal evidence base and authoritative sources that underpin the clinical content of Volume 2. Learners are encouraged to access primary literature for the key treatment trials and consensus documents listed below, as familiarity with the original research supports both examination performance and clinical confidence in practice discussions with patients and colleagues.

Trichoscopy and Dermoscopy

- Rudnicka L et al. *Atlas of Trichoscopy* — the foundational image-based reference for dermoscopic hair and scalp assessment
- Kossard S and Sinclair R — foundational work on trichoscopic pattern recognition in scarring and non-scarring alopecias
- Rakowska A et al. — trichoscopic criteria for AGA in men and women; sensitivity and specificity studies
- International Dermoscopy Society trichoscopy guidelines and consensus documents

Male AGA Treatment Evidence

- Kaufman KD et al. — landmark finasteride RCT (NEJM 1998) establishing efficacy in male AGA
- van Zuuren EJ et al. — Cochrane systematic review of interventions for AGA
- Sinclair R et al. — low-dose oral minoxidil studies; safety and efficacy data
- Olsen EA et al. — pivotal dutasteride RCTs and comparison with finasteride

Female Hair Loss

- Sinclair R — female pattern hair loss classification and management review
- Shapiro J — comprehensive female hair loss clinical review and differential diagnosis frameworks
- Vañó-Galván S et al. — frontal fibrosing alopecia consensus recommendations and evidence review
- Mirmirani P et al. — primary cicatricial alopecias: approach and classification

Investigations and Biopsy Logic

- Headington JT — transverse microscopic anatomy of the scalp; foundational horizontal sectioning paper
- Sperling LC — scalp biopsy: how to optimise the yield
- Tosti A and Piraccini BM — hair loss and the hormonal and nutritional differential; textbook chapters
- Olsen EA et al. — summary of evidence for ferritin thresholds in female hair loss

Regenerative Medicine

- Gupta AK et al. — systematic reviews of PRP for AGA: meta-analyses and grade of evidence
- Hausauer AK and Jones DH — microneedling and minoxidil combination RCT evidence
- Giordano S et al. — PRP in male and female AGA: systematic review and meta-analysis
- Emerging exosome literature: Qi J et al. and ongoing registered clinical trials (clinicaltrials.gov)

Surgical Hair Restoration

- International Society of Hair Restoration Surgery (ISHRS) — practice guidelines and annual census data
- Unger W and Shapiro R — *Hair Transplantation* textbook, standard surgical reference
- Bernstein RM and Rassman WR — follicular unit transplantation foundational papers
- ISHRS consensus on donor assessment, candidacy criteria, and long-term outcomes documentation

End-of-Volume 2 Comprehensive Assessment

The following comprehensive assessment prompts span all five modules of Volume 2 and are designed to test integrated clinical reasoning rather than isolated factual recall. These prompts mirror the structure of the IIIOHR Advanced Trichology Academy certification examination and should be approached as structured written or verbal case presentations. Model answers are available on the LMS platform following satisfactory completion of all module-level assessments.

01

Case Reasoning: The Young Man with Rapidly Progressive Loss

A 23-year-old man presents with a six-month history of rapid frontotemporal recession and crown thinning. His father has Norwood 6 AGA. Trichoscopy shows marked anisotrichosis in frontal and crown zones. He requests a hair transplant. Describe your complete consultation approach, including examination, trichoscopy interpretation, investigation decision, treatment recommendation, surgical candidacy assessment, and counselling framework.

02

Case Reasoning: The Woman with Mixed Presentation

A 36-year-old woman presents with 14 months of progressive central part widening, fatigue, irregular menstrual cycles averaging every 35–40 days, and moderate facial acne. Her mother has visible crown thinning. Outline your structured differential diagnosis, investigation strategy with justification for each test, and treatment plan with reproductive counselling included.

03

Trichoscopy Interpretation Exercise

You examine a 45-year-old woman referred with 'female pattern hair loss not responding to minoxidil after 18 months.' Trichoscopy shows: yellow dots across all scalp zones including occipital, tapered hairs in the frontal zone, no peripilar sign, minimal shaft diameter diversity, and no loss of follicular openings. What is your diagnostic conclusion, and how does it change management?

04

Biopsy Logic Exercise

A 52-year-old postmenopausal woman presents with a two-year history of progressive frontotemporal recession. She has mild pruritus and reports eyebrow thinning bilaterally. Trichoscopy at the hairline margin shows perifollicular erythema and peripilar scale. Describe the diagnosis you suspect, the optimal biopsy site and technique, the information you would include on the pathology request form, and the implications for management.

05

Treatment Failure Analysis

A 31-year-old man with Norwood 4 AGA has been on topical 5% minoxidil for 12 months and reports no improvement. He is frustrated and considering stopping all treatment. Conduct a structured failure analysis addressing: diagnostic completeness, treatment adequacy and adherence, expectation calibration, the role of combination therapy, and how you would restructure the treatment plan.

Volume 2 at a Glance: Quick-Reference Summary Card

This summary card consolidates the most clinically actionable content from each module for rapid review and pre-examination revision. It is designed as a synthesis tool, not a replacement for the detailed module content.

Module 5: Examination

- Observe pattern, camouflage, and symptoms before instruments
- Distinguish density loss vs. calibre reduction vs. breakage
- Pull test: perform in multiple zones; interpret with context
- Club root = shed telogen; no root, variable length = breakage
- Eight-view photography before any intervention
- Red flags: rapid progression, loss of ostia, scalp pain, pustulation

Module 6: Trichoscopy

- Always compare affected zone vs. occipital control
- AGA: anisotrichosis, peripilar sign, reduced hairs/unit patterned
- AA: yellow dots, black dots, exclamation mark hairs, tapered hairs
- Scarring: loss of ostia, perifollicular scale/erythema, tufting
- Biopsy target: active margin, not burned-out centre
- Diffuse AA incognita: yellow dots at occipital reference — critical sign

Module 7: Investigations and Biopsy

- Investigate phenotype-led, not reflexively
- Core: FBC, ferritin + iron studies, thyroid function
- Androgen panel: only with hyperandrogenic clues in women
- Ferritin: interpret with full iron panel and clinical context
- Biopsy: active margin; send full clinical information with specimen
- Horizontal sections: follicle counts. Vertical: interface inflammation

Module 8: Male AGA

- Stage with Norwood-Hamilton + qualitative donor/calibre description
- Medical ladder: topical/oral minoxidil + finasteride ± dutasteride
- PRP: adjunctive, not substitute for medical therapy
- Surgery: assess donor trichoscopically; young + aggressive = caution
- Crown grafts: defer if progressive disease or limited donor
- Initial minoxidil shedding: expected and temporary

Module 9: Female Hair Loss

- FPHL is phenotypically diverse: central, frontal, diffuse volume all valid
- Normal androgens do not exclude androgenetic follicular miniaturisation
- Always consider mixed aetiology: FPHL + TE + iron + thyroid
- Reproductive counselling mandatory before spironolactone/finasteride
- Postpartum shedding may unmask underlying FPHL at 12+ months
- Surgery: confirm stable donor trichoscopically; defer if diffuse loss active

Preparing for Volume 3: What Comes Next

Volume 3 of the HLI/IIIOHR Advanced Trichology Academy curriculum builds directly on the diagnostic foundations established here. The diagnostic competence developed in Volume 2 — the ability to accurately identify condition, phenotype, severity, contributing factors, and individual patient context — is the essential prerequisite for the advanced therapeutic decision-making that Volume 3 addresses. A treatment plan is only as good as the diagnosis on which it is built, and the physician who cannot reliably distinguish FPHL from chronic telogen effluvium, or uncomplicated male AGA from early cicatricial disease, will apply even the most sophisticated pharmacological protocols to incorrect targets with correspondingly poor results.

Advanced Pharmacology and Combination Therapy

Volume 3 covers the full pharmacological treatment landscape in depth, including emerging agents, off-label treatments with developing evidence, combination therapy logic, treatment sequencing, managing side effects, and the science of treatment resistance. The foundational treatment frameworks introduced in Modules 8 and 9 will be significantly extended.

Regenerative Medicine Protocols

PRP preparation protocols, platelet concentration standards, activation methods, treatment intervals, combination with microneedling and minoxidil, and the emerging exosome and stem-cell-derived secretome landscape are covered in clinical and scientific depth. Outcome monitoring frameworks are also included.

Treatment Monitoring and Outcomes Assessment

Volume 3 addresses how to systematically monitor treatment response using serial photography, global photography grading, trichoscopic density assessment, patient-reported outcomes, and objective scalp imaging tools. Failure analysis frameworks are developed further, and decision points for treatment escalation are specified.

Management of Inflammatory and Overlap Conditions

The treatment of seborrhoeic dermatitis, psoriasis-related hair loss, and early-stage cicatricial alopecias that coexist with pattern hair loss is addressed in Volume 3, building on the diagnostic identification skills developed in this volume. The interface between trichology and general dermatology practice is explored.

> *"Diagnosis is not the end of clinical thinking — it is the beginning of therapeutic reasoning. Every treatment decision in hair loss medicine is only as strong as the diagnostic platform on which it rests. Volume 2 builds that platform."*
>
> — HLI/IIIOHR Advanced Trichology Academy

MCQ ASSESSMENT

Volume 2: Multiple Choice Assessment

Modules 5–9 | 10 Questions

Select the single best answer for each question. These questions test integrated clinical reasoning across all five modules of Volume 2.

1. (Module 5 – Clinical Examination) A patient presents with diffuse hair thinning. On global visual inspection, the part-line appears widened centrally but the frontal hairline is preserved. Which pattern does this most suggest?
   A. Norwood Stage III male AGA
   B. Ludwig Type I female pattern hair loss
   C. Diffuse alopecia areata
   D. Frontal fibrosing alopecia
2. (Module 5 – Hair Pull Test) A positive hair pull test yielding more than 6 telogen hairs from a single region is most consistent with:
   A. Androgenetic alopecia in the anagen-dominant phase
   B. Active telogen effluvium or an unstable alopecia areata
   C. Traction alopecia
   D. Normal physiological shedding
3. (Module 6 – Trichoscopy) Which trichoscopic finding is considered the single most reliable indicator of scarring alopecia?
   A. Yellow dots
   B. Black dots
   C. Loss of follicular openings (absence of ostia)
   D. Peripilar casts
4. (Module 6 – Trichoscopy) Anisotrichosis on trichoscopy refers to:
   A. Absence of hair shafts in a defined zone
   B. Variation in hair shaft diameter within the same follicular unit or region
   C. Perifollicular scaling around the follicular ostia
   D. Increased vellus-to-terminal hair ratio
5. (Module 6 – Alopecia Areata) Exclamation mark hairs on trichoscopy are pathognomonic of:
   A. Trichotillomania
   B. Alopecia areata at the active margin
   C. Lichen planopilaris
   D. Androgenetic alopecia
6. (Module 7 – Laboratory Workup) In a woman presenting with diffuse shedding and fatigue, which single laboratory marker is most important to assess as a first-line investigation?
   A. Total testosterone
   B. Serum ferritin
   C. Prolactin
   D. DHEA-S
7. (Module 7 – Biopsy) Horizontal sectioning of a scalp biopsy is preferred over vertical sectioning primarily because:
   A. It allows better assessment of the dermal-epidermal junction
   B. It samples a greater number of follicular units and allows follicular density counting
   C. It is technically easier to perform
   D. It reduces the risk of scarring at the biopsy site
8. (Module 8 – Male AGA Treatment) Which of the following is the correct mechanism of action of finasteride in male AGA?
   A. Direct stimulation of the androgen receptor in the dermal papilla
   B. Inhibition of 5-alpha reductase type II, reducing DHT conversion
   C. Blockade of the mineralocorticoid receptor in the scalp
   D. Promotion of anagen re-entry via prostaglandin pathway activation
9. (Module 9 – Female Pattern Hair Loss) Which classification system is most widely used to grade female pattern hair loss severity?
   A. Norwood-Hamilton scale
   B. Ludwig scale
   C. Sinclair scale
   D. Both B and C are commonly used
10. (Module 9 – Reproductive Life Stage) Postpartum telogen effluvium typically presents at what interval following delivery?
   A. Immediately at delivery
   B. 2–4 weeks postpartum
   C. 2–4 months postpartum
   D. 6–12 months postpartum

ANSWER KEY

Volume 2 MCQ: Answer Key & Explanations

Review your answers below. Each correct answer is followed by a brief clinical rationale.

1. Correct Answer: B – Ludwig Type I FPHL
Widening of the central part-line with preservation of the frontal hairline is the hallmark of Ludwig-pattern female hair loss. Norwood III involves frontotemporal recession. Diffuse AA and FFA have distinct distribution patterns.

2. Correct Answer: B – Active telogen effluvium or unstable alopecia areata
A positive pull test with >6 telogen hairs indicates active shedding. In stable AGA, the pull test is typically negative. Traction alopecia and normal shedding do not produce a positive pull test result.

3. Correct Answer: C – Loss of follicular openings (absence of ostia)
Absent follicular ostia represent permanent follicular destruction and are the most reliable trichoscopic marker of scarring alopecia. Yellow dots suggest follicular plugging (as in AA or AGA), and black dots indicate broken or cadaverised hairs.

4. Correct Answer: B – Variation in hair shaft diameter within the same follicular unit or region
Anisotrichosis describes the coexistence of thick and thin (miniaturised) hairs within the same zone, a key trichoscopic feature of androgenetic alopecia. It reflects the progressive miniaturisation process driven by DHT.

5. Correct Answer: B – Alopecia areata at the active margin
Exclamation mark hairs — tapered, broken hairs thinner at the base — are a hallmark of active alopecia areata. They reflect anagen arrest and peribulbar lymphocytic attack. They are not seen in AGA, LPP, or trichotillomania.

6. Correct Answer: B – Serum ferritin
Iron deficiency is the most common reversible systemic cause of diffuse shedding in women. Serum ferritin is the most sensitive marker of iron stores. Androgens and prolactin are relevant in specific subsets but are not first-line in undifferentiated diffuse shedding.

7. Correct Answer: B – It samples a greater number of follicular units and allows follicular density counting
Horizontal (transverse) sectioning cuts across multiple follicular units simultaneously, enabling accurate terminal-to-vellus ratio assessment and follicular density counting. Vertical sectioning is better for interface pathology but samples fewer follicles.

8. Correct Answer: B – Inhibition of 5-alpha reductase type II, reducing DHT conversion
Finasteride competitively inhibits the type II isoenzyme of 5-alpha reductase, reducing scalp and serum DHT by approximately 60–70%. It does not act on the androgen receptor directly, nor does it involve mineralocorticoid or prostaglandin pathways.

9. Correct Answer: D – Both B and C are commonly used
The Ludwig scale (3 grades) and the Sinclair scale (5 grades) are both widely used in clinical practice and research for grading FPHL severity. The Norwood-Hamilton scale is designed for male pattern hair loss and is not appropriate for female patients.

10. Correct Answer: C – 2–4 months postpartum
Postpartum telogen effluvium typically manifests 2–4 months after delivery, corresponding to the synchronised shift of hairs that entered telogen at the end of pregnancy. The delay reflects the normal 2–3 month telogen phase duration before shedding occurs.